



OPEN ACCESS

Lessons from the trials

DECAAF: Emphasizing the importance of MRI in AF ablation

Mohamed ElMaghawry^{1,*}, Soha Romeih²

¹Department of Cardiology,
Aswan Heart Centre, Egypt
²Departments of Pediatric
Cardiology/Radiology,
Aswan Heart Centre, Egypt
*Email: Maghawry79@gmail.com

ABSTRACT

Atrial fibrillation ablation is a complex and challenging procedure. Appropriate patient selection is the most critical step to ensure safe and successful atrial fibrillation ablation procedure. The DECAAF study (Delayed-Enhancement MRI Determinant of Successful Radiofrequency Catheter Ablation of Atrial Fibrillation) showed that atrial tissue fibrosis, as estimated by delayed enhancement magnetic resonance imaging, was independently associated with recurrent arrhythmia post atrial fibrillation ablation. Magnetic resonance imaging also detected left atrial volume and shape. Integrating the data provided by magnetic resonance imaging into the pre-procedural planning is crucial.

[http://dx.doi.org/
10.5339/gcsp.2015.8](http://dx.doi.org/10.5339/gcsp.2015.8)

Submitted: 11 January 2015
Accepted: 18 February 2015
© 2015 ElMaghawry, Romeih,
licensee Bloomsbury Qatar
Foundation Journals. This is an open
access article distributed under
the terms of the Creative Commons
Attribution license CC BY 4.0,
which permits unrestricted use,
distribution and reproduction in
any medium, provided the original
work is properly cited.

BACKGROUND

Atrial fibrillation (AF) is the most common arrhythmia in clinical practice and is associated with increased morbidity, mortality, and additionally represents a financial burden in healthcare. Over the past decade, catheter ablation has become an important therapeutic modality for patients with symptomatic, drug refractory, AF. However, catheter ablation of AF is not risk-free, and potentially life threatening complications can arise, such as an atrio-oesophageal fistula, stroke, and cardiac tamponade¹. The rates of these adverse events have been consistently dropping with the gained experience in ablation techniques over the last decade. Despite this growing experience, high rates of early and late AF recurrence remains the Achilles' heel of catheter ablation of AF^{2,3}. Many studies have targeted the predictors of AF recurrence, such as patients' age and gender, left atrial size, type and duration of AF, left ventricular systolic dysfunction or heart failure, structural or valvular heart disease, and number of attempted ablation procedures^{4,5}. Among these predictors, left atrial fibrosis has been established as an independent determinant for success of rhythm control strategies in AF. The DECAAF trial studied atrial tissue fibrosis estimation by delayed enhancement magnetic resonance imaging (DE-MRI) and its association with subsequent AF ablation outcome⁶.

DECAAF: DESIGN AND OUTCOMES

Delayed-Enhancement MRI Determinant of Successful Radiofrequency Catheter Ablation of Atrial Fibrillation (DECAAF) was a multicenter, prospective, observational cohort study of patients diagnosed with paroxysmal and persistent AF, and undergoing their first catheter ablation, conducted between August 2010 and August 2011 at 15 centers in the United States, Europe, and Australia. DE-MRI images were obtained up to 30 days before ablation. Fibrosis quantification was performed at a core laboratory blinded to the participating center, ablation approach, and procedure outcome. Cumulative incidence of recurrence was estimated by stage at days 325 and 475 after a 90-day blanking period, which is the standard time allowed for arrhythmias related to ablation-induced inflammation to subside. The risk of recurrence was estimated after adjusting for 10 demographic and clinical covariates.

In total, 260 patients with atrial fibrillation, including 65% with paroxysmal atrial fibrillation, were included in the study. All patients underwent a pre-ablation MRI up to 30 days before the procedure and 90 days following the ablation. Based on the degree of atrial remodeling/fibrosis, patients were classified into four groups: stage 1 (<10% fibrosis), stage 2 (>10% to <20% fibrosis), stage 3 (>20% to <30% fibrosis), and stage 4 (>30% fibrosis) (Figure 1).

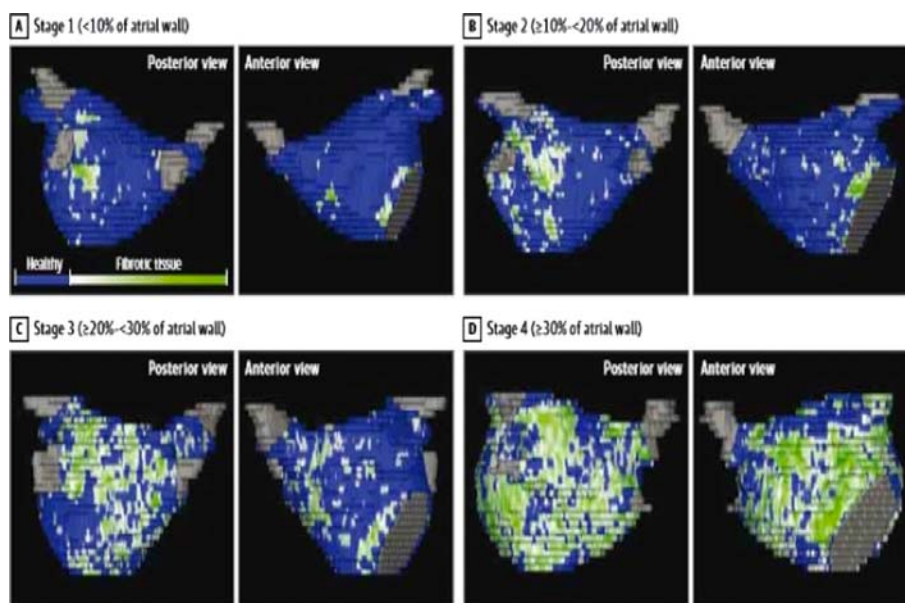


Figure 1. shows four stages of left atrial tissue fibrosis based on 3D delayed enhancement magnetic resonance imaging scans. Normal left atrial wall is displayed in blue, fibrotic changes are in green and white, the pulmonary veins and mitral valve are shown in gray. Stages 1 through 4 show increasing amounts of fibrosis as a percentage of the total left atrial wall volume. (N. Marrouche et al. JAMA. 2014; 311 (5): 498–506).

After adjustment for multiple variables, including age, gender, hypertension, comorbidities, type of atrial fibrillation, left atrial volume, and left ventricular ejection fraction, the extent of atrial disease was the only significant predictor of atrial-fibrillation recurrence. Each 1% increase in the extent of atrial fibrosis was associated with a significant 5.8% increased risk of recurrence post-ablation. For patients classified with stage 1 fibrosis, 84.6% were free from the arrhythmia at one year compared with just 31% of patients with stage 4 fibrosis. Overall, 64% and 54% of patients with stage 2 and 3 fibrosis were arrhythmia-free at one year.

DISCUSSION

There is a consistent body of evidence showing that left atrial remodelling has deterministic value in the development and progression of AF. It was proven since 1980's that the size of the left atrium correlates with AF incidence. Several studies have examined the relation between the echocardiographic left atrial dimensions and the development of AF. In the Framingham Heart Study, individuals in the highest quartile of left atrial diameter (> 44 mm) had approximately 2.5 times the risk of developing AF compared with individuals in the lowest quartile of left atrial diameter (< 35 mm) after adjusting for age and sex⁷. The Cardiovascular Health Study cohort observed similar results⁸. Furthermore, it was observed that patients with dilated left atria are also more likely to relapse after ablation of AF, making left atrial size a well established risk factor for AF recurrence after AF ablation⁹.

Recently, the concept of left atrial remodelling has evolved beyond simple left atrial size quantification. Single centre studies have proven efficacy of DE-MRI at the atrial level in evaluation atrial fibrosis as an arrhythmogenic substrate^{10,11}. These findings were further confirmed by the current multicenter DECAAF trial.

Beyond scar detection by DE-MRI, a new non-invasive shape-based remodelling parameter, left atrial sphericity, which uses magnetic resonance angiography, was strongly and independently associated with AF recurrences post ablation¹². In addition, the periatrial, periventricular and total pericardial fat volumes, detected by MRI, were found to be associated with poorer post AF ablation¹³.

Post-AF ablation, MRI can assess the degree left atrial reverse remodelling by detecting decrease in left atrial size¹⁴. Furthermore, in cases of AF recurrence, MRI can guide electrophysiologists to localise the reconnection sites at the ablation lines¹⁵ (Figure 2).

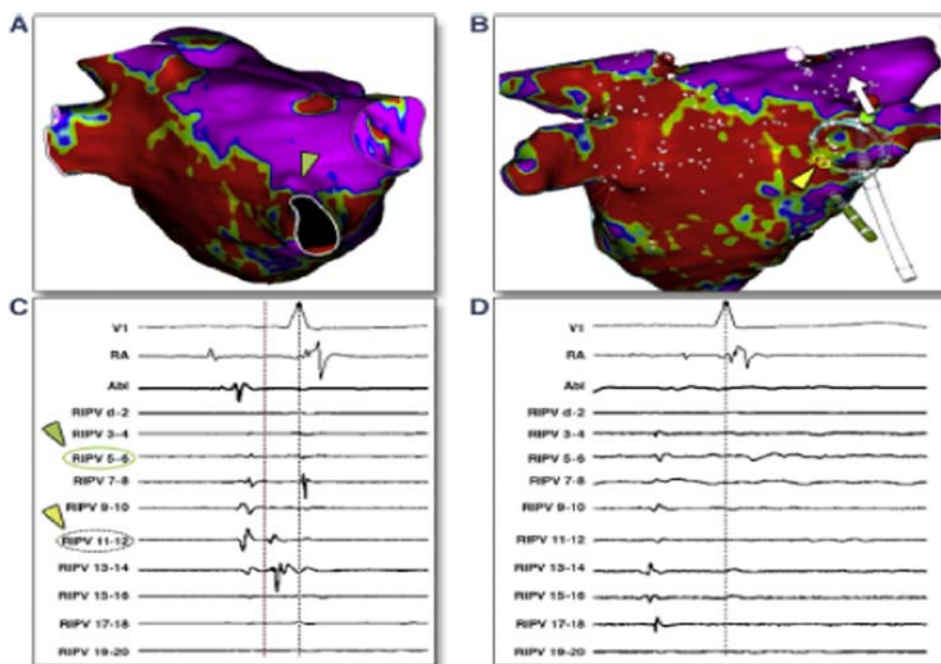


Figure 2. This example highlights the Lasso catheter's limitations in locating the reconnection site and the usefulness of DE-CMR. (A) DE-CMR model showing a gap at the superior part of the right inferior pulmonary vein (RIPV) (green arrowhead). (B) Ablation catheter at anatomic gap site. Lasso catheter positioned at RIPV shows (C) earliest activation at dipole 11 to 12 (yellow arrowhead) that corresponds to the inferoposterior part of RIPV. (D) Radiofrequency application at CMR gap (dipole 5 to 6) led to pulmonary vein isolation. (Bisbal et al. JACC: cardiovascular imaging, vol.7, No 7, 2014).

DISCUSSION AND CRITIQUE

Although DE-MRI provides reliable staging of atrial disease, the inherent technical limitations of the imaging technique, such as the spatial resolution applied to the thin atrial wall, may limit its use on broader spectrum.

Moreover, no correlation was found between the extent of left atrial fibrosis and the duration or type of AF. Previous studies have demonstrated patients with paroxysmal AF have a large fibrosis, while other patients with persistent AF show only mild degrees of fibrosis. Similar results were observed in the DECAAF study, where the number of patients with paroxysmal AF was highest in the group with the most extensive fibrosis (79.2% paroxysmal AF in grade 4 fibrosis vs. 65.3% in grade 1). These findings do not support a causal relationship in which AF produces fibrosis, instead of being a consequence of a more complex left atrial fibrotic process¹⁶.

In addition, the method by which investigators detected AF recurrence is not clear. In fact, the diagnosis of AF recurrences based only on symptoms reported by patients is of no true clinical value. The absence of symptoms must not be simply interpreted as absence of AF. Moreover, many of the palpitations reported post AF ablation are due to supraventricular extra beats rather than AF episodes. Conventional Holter monitoring can only provide a snapshot documentation of the underlying heart rhythm for 24 hours up to 7 days, failing to detect arrhythmic episodes beyond this very limited time window. On the other hand, implantable continuous heart rhythm monitor devices (loop recorder) represent a promising option to detect the true AF burden post-ablation.

Further studies will be needed in order to implement the important results of DECAAF into a wider clinical context, for example, to evaluate the clinical outcomes of using high scar index as an exclusion criterion from AF ablation procedures. Other attractive research point is to integrate data on left atrial fibrosis detected by MRI with the electrophysiological properties of the left atrium assessed using voltage mapping and identification of complex fractionated electrograms.

WHAT HAVE WE LEARNT?

AF ablation is a challenging procedure. Appropriate patient selection is the most critical step to ensure safe and successful AF ablation procedure. Integrating data on left atrial anatomy, size, shape, and degree of fibrosis provided by MRI into pre-procedural planning is crucial (Figure 3).

This is particularly imperative in centers still in their initial AF ablation experience. Yet, it is important to acknowledge other processes affecting the electrical, molecular, contractile and structural properties of the atria that are necessary for the initiation and maintenance of AF. Therefore, we need to recognize the data about left atrial fibrosis, and the whole concept of AF ablation, within a wider context in which AF is a complex, multi-factorial progressive disorder¹⁷.

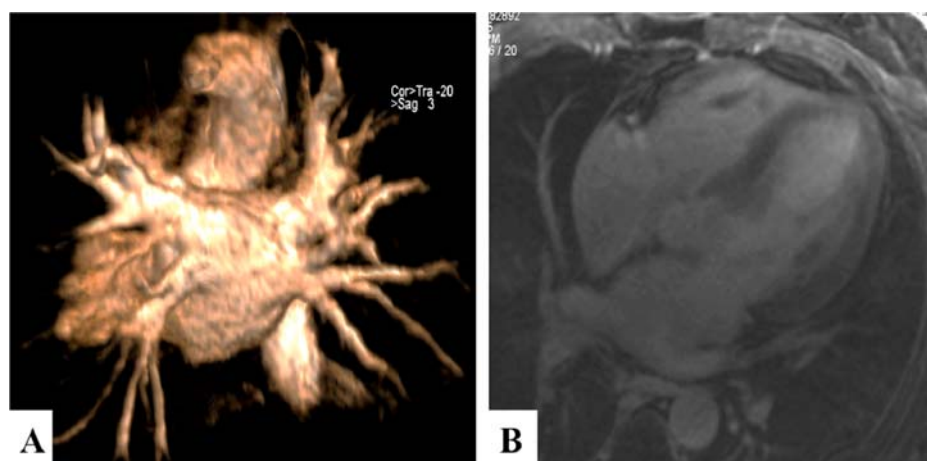


Figure 3. Magnetic resonance imaging of a 50 year old male patient presenting in Aswan Heart Centre before pulmonary vein isolation procedure for recurrent symptomatic paroxysmal AF despite being on Class III antiarrhythmic. (A) 3D reconstructing of magnetic resonance pulmonary veins angiography (PA view) demonstrating the site of entry of each pulmonary vein. (B) 2D delayed contrast hyperenhancement demonstrating no fibrosis of left atrium tissue.

REFERENCES

- [1] Haegeli LM, Calkins H. Catheter ablation of atrial fibrillation: an update. *Eur Heart J*. [Internet]. 2014; Available from: <http://www.ncbi.nlm.nih.gov/pubmed/25053659>
- [2] Tzou WS, Marchlinski FE, Zado ES, Lin D, Dixit S, Callans DJ, Cooper JM, Bala R, Garcia F, Hutchinson MD, Riley MP, Verdino R. Long-term outcome after successful catheter ablation of atrial fibrillation. *Circ Arrhythmia Electrophysiol*. 2010;3:237–242.
- [3] Bertaglia E, Tondo C, De Simone A, Zoppo F, Mantica M, Turco P, Iuliano A, Forleo G, La Rocca V, Stabile G. Does catheter ablation cure atrial fibrillation? Single-procedure outcome of drug-refractory atrial fibrillation ablation: A 6-year multicentre experience. *Europace*. 2010;12:181–187.
- [4] Berruezo A, Tamborero D, Mont L, Benito B, Tolosana JM, Sitges M, Vidal B, Arriagada G, Méndez F, Matiello M, Molina I, Brugada J. Pre-procedural predictors of atrial fibrillation recurrence after circumferential pulmonary vein ablation. *Eur Heart J*. 2007;28:836–841.
- [5] Arya A, Hindricks G, Sommer P, Huo Y, Bollmann A, Gaspar T, Bode K, Husser D, Kottkamp H, Piorkowski C. Long-term results and the predictors of outcome of catheter ablation of atrial fibrillation using steerable sheath catheter navigation after single procedure in 674 patients. *Europace*. 2010;12:173–180.
- [6] Marrouche NF, Wilber D, Hindricks G, Jais P, Akoum N, Marchlinski F, Kholmovski E, Burgon N, Hu N, Mont L, Deneke T, Duytschaever M, Neumann T, Mansour M, Mahnkopf C, Herweg B, Daoud E, Wissner E, Bansmann P, Brachmann J. Association of atrial tissue fibrosis identified by delayed enhancement MRI and atrial fibrillation catheter ablation: the DECAAF study. *JAMA*. 2014;311:498–506. [Internet]. Available from: <http://www.ncbi.nlm.nih.gov/pubmed/24496537>
- [7] Vaziri SM, Larson MG, Benjamin EJ, Levy D. Echocardiographic predictors of nonrheumatic atrial fibrillation. *The Framingham Heart Study*. *Circulation*. 1994;89:724–730.
- [8] Rosenberg MA, Gottdiener JS, Heckbert SR, Mukamal KJ. Echocardiographic diastolic parameters and risk of atrial fibrillation: The cardiovascular health study. *Eur Heart J*. 2012;33:904–912.
- [9] Hof I, Chilukuri K, Arbab-Zadeh A, Scherr D, Dalal D, Nazarian S, Henrikson C, Spragg D, Berger R, Marine J, Calkins H. Does left atrial volume and pulmonary venous anatomy predict the outcome of catheter ablation of atrial fibrillation? *J Cardiovasc Electrophysiol*. 2009;20:1005–1010.
- [10] Oakes RS, Badger TJ, Kholmovski EG, Akoum N, Burgon NS, Fish EN, Blauer JJ, Rao SN, DiBella EV, Segerson NM, Daccarett M, Windfelder J, McGann CJ, Parker D, MacLeod RS, Marrouche NF. Detection and quantification of left atrial structural remodeling with delayed-enhancement magnetic resonance imaging in patients with atrial fibrillation. *Circulation*. 2009;119:1758–1767.
- [11] Akoum N, Daccarett M, McGann C, Segerson N, Vergara G, Kuppahally S, Badger T, Burgon N, Haslam T, Kholmovski E, Macleod R, Marrouche N. Atrial fibrosis helps select the appropriate patient and strategy in catheter ablation of atrial fibrillation: A DE-MRI guided approach. *J Cardiovasc Electrophysiol*. 2011;22:16–22.
- [12] Bisbal F, Guiu E, Calvo N, Marin D, Berruezo A, Arbelo E, Ortiz-Pérez J, de Caralt TM, Tolosana JM, Borrás R, Sitges M, Brugada J, Mont L. Left atrial sphericity: A new method to assess atrial remodeling. impact on the outcome of atrial fibrillation ablation. *J Cardiovasc Electrophysiol*. 2013;24:752–759.
- [13] Wong CX, Abed HS, Molaee P, Nelson AJ, Brooks AG, Sharma G, Leong DP, Lau DH, Middeldorp ME, Roberts-Thomson KC, Wittert GA, Abhayaratna WP, Worthley SG, Sanders P. Pericardial fat is associated with atrial fibrillation severity and ablation outcome. *J Am Coll Cardiol*. 2011;57:1745–1751.
- [14] Bisbal F, Guiu E, Cabanas P, Calvo N, Berruezo A, Tolosana JM, Arbelo E, Vidal B, de Caralt TM, Sitges M, Brugada J, Mont L. Reversal of spherical remodelling of the left atrium after pulmonary vein isolation: Incidence and predictors. *Europace*. 2014;16:840–847.
- [15] Bisbal F, Guiu E, Cabanas-Grandío P, Berruezo A, Prat-Gonzalez S, Vidal B, Garrido C, Andreu D, Fernandez-Armenta J, Tolosana JM, Arbelo E, de Caralt TM, Perea RJ, Brugada J, Mont L. CMR-guided approach to localize and ablate gaps in repeat AF ablation procedure. *JACC Cardiovasc Imaging*. 2014;7:653–663.
- [16] Kottkamp H. Human atrial fibrillation substrate: Towards a specific fibrotic atrial cardiomyopathy. *European Heart Journal*. 2013;2731–2738.
- [17] Kallergis EM, Goudis CA, Vardas PE. Atrial fibrillation: A progressive atrial myopathy or a distinct disease? *International Journal of Cardiology*. 2014;126–133.