



OPEN ACCESS

Review article

Bioresorbable scaffolds for percutaneous coronary interventions

Bill D. Gogas*

Andreas Gruentzig Cardiovascular Center, Department of Medicine, Division of Cardiology, Emory University School of Medicine, Atlanta, GA
*Email: vasileios.gkogkas@emory.edu

ABSTRACT

Innovations in drug-eluting stents (DES) have substantially reduced rates of in-segment restenosis and early stent thrombosis, improving clinical outcomes following percutaneous coronary interventions (PCI). However a fixed metallic implant in a vessel wall with restored patency and residual disease remains a precipitating factor for sustained local inflammation, in-stent neo-atherosclerosis and impaired vasomotor function increasing the risk for late complications attributed to late or very late stent thrombosis and late target lesion revascularization (TLR) (late catch-up).

The quest for optimal coronary stenting continues by further innovations in stent design and by using biocompatible materials other than cobalt chromium, platinum chromium or stainless steel for engineering coronary implants. Bioresorbable scaffolds made of biodegradable polymers or biocorrosible metals with properties of transient vessel scaffolding, local drug-elution and future restoration of vessel anatomy, physiology and local hemodynamics have been recently developed. These devices have been utilized in selected clinical applications so far providing preliminary evidence of safety showing comparable performance with current generation drug-eluting stents (DES).

Herein we provide a comprehensive overview of the current status of these technologies, we elaborate on the potential benefits of transient coronary scaffolds over permanent stents in the context of vascular reparation therapy, and we further focus on the evolving challenges these devices have to overcome to compete with current generation DES.

Condensed Abstract:

The quest for optimizing percutaneous coronary interventions continues by iterative innovations in device materials beyond cobalt chromium, platinum chromium or stainless steel for engineering coronary implants. Bioresorbable scaffolds made of biodegradable polymers or biocorrosible metals with properties of transient vessel scaffolding; local drug-elution and future restoration of vessel anatomy, physiology and local hemodynamics were recently developed. These devices have been utilized in selected clinical applications providing preliminary evidence of safety showing comparable intermediate term clinical outcomes with current generation drug-eluting stents.

Keywords: bioresorbable scaffolds, coronary revascularization, invasive multimodality imaging

Abbreviations: BMS = bare-metal stents; BRS = bioresorbable scaffolds; CCTA = coronary computed tomographic angiography; DES = drug-eluting stents; FDA = food and drug administration; FIM = first-in-man; IVUS = intravascular ultrasound; MACE = major adverse cardiovascular events; OCT = optical coherence tomography; PCI = percutaneous coronary intervention; PLLA = poly-L-lactic acid; TLR = target lesion revascularization

<http://dx.doi.org/10.5339/gcsp.2014.55>

Submitted: 9 October 2014

Accepted: 11 December 2014

© 2014 Gogas, licensee Bloomsbury Qatar Foundation Journals. This is an open access article distributed under the terms of the Creative Commons Attribution license CC BY 4.0, which permits unrestricted use, distribution and reproduction in any medium, provided the original work is properly cited.

INTRODUCTION

Balloon angioplasty firstly performed by Andreas R. Gruentzig in 1977 changed the landscape of coronary artery disease treatment; meanwhile the technique was plagued by several drawbacks including eccentric intimal and media dissections, acute vessel recoil or subacute closure, late constrictive remodeling and a diffuse proliferative response leading to diffuse restenosis.¹ Further technological advances prompted the development of bare-metal stents (BMS) which replaced balloon angioplasty as the preferred method of coronary revascularization showing superior angiographic and clinical outcomes.² Restenosis rates with bare-metal stents were reported to be between 16% and 44%, with higher rates of stenosis attributed to several risk factors, in particular long lesions and small vessel calibers.

First generation DES with permanent polymers were the next step in tackling the iatrogenic entity of neointimal hyperplasia with reductions in restenosis rates down to 0% in highly selective lesions and up to 16% in a broader range of patients and clinical subsets.³ Despite these impressive results which led US Food and Drug Administration (FDA) to approve clinical use of 1st generation DES in 2003, there is growing evidence showing that permanent metallic materials coated with durable polymers are associated with endothelial dysfunction, delayed endothelialization and local hypersensitivity reactions, increasing the risk of late or very late stent thrombosis.⁴⁻⁸

Despite innovations in platform design such as reductions in strut thickness, implementation of novel antiproliferative agents, and more biocompatible coatings such as bioresorbable polymers the permanent metallic prosthesis remains a precipitating factor for sustained vascular inflammation, in-stent neoatherosclerosis and impaired vasomotor function.⁹⁻¹⁶

Therefore, the concept of a drug-eluting bioresorbable scaffold (BRS) with properties of temporary vessel scaffolding (~6-months) and long-term restoration of vessel anatomy, physiology and functionality when the device is fully resorbed is appealing. Several drug-eluting BRS made of biodegradable polymers or biocorrosible metals have been developed and tested in first-in-man (FIM) studies showing encouraging imaging and clinical results up to 3-years follow-up thus far. These endeavors have led the gradual maturation of a novel field in interventional cardiovascular medicine, that of vascular restoration therapy.¹⁷








TRANSIENT BIORESORBABLE SCAFFOLDS VS. PERMANENT METALLIC STENTS

The impetus for developing drug-eluting BRS for the treatment of obstructive coronary artery disease was driven by the need for an elastic, conformable and transient scaffold instead of a stiff and permanent metallic implant to prevent acute and late recoil, seal post-procedural dissections following barotrauma and inhibit in-segment restenosis utilizing appropriate drug-elution. This technological endeavor would overcome long-term implications of rigid metal caging following deployment of a stiff device in a previously pulsatile vascular tissue.

The use of biodegradable materials such as synthetic polymers for developing BRS was investigated by van der Giessen et al. who performed animal experiments by deploying stents made of 5 biodegradable polymers: polyglycolic acid/ poly-lactic acid, poly caprolactone, and polyethyleneoxide/polybutylene terephthalate and deploying them in porcine coronary arteries. The first observations were disappointing showing marked inflammatory reaction with subsequent exaggerated neointimal thickening; and ongoing bench studies in this field indicated that polymer molecular weight was a major determinant of the observed vascular responses.¹⁸

Further research demonstrated that high-molecular-weight polymers like high-molecular-weight poly-L-lactic acid (PLLA) which is the L-isomer (L: levo or left) of poly lactic acid performed better when compared to low-molecular-weight PLLA which precipitated intense inflammatory response and aggressive neointimal hyperplasia. Current BRS technologies are either polymer or metal (magnesium) alloys with PLLA being the most commonly used polymer; however tyrosine derived polycarbonates and poly (anhydride-esters) composed of salicylic acid have been also used as polymer matrices (Table 1). The advantages of fully bioresorbable scaffolds vs. permanent metallic stents remain to be elucidated by pursuing large scale randomized trials with strong clinical end points; meanwhile preliminary observations from multicenter registries outside the US have already indicated the potentialities of these technologies which may further reduce the rates of late restenosis and late or very late scaffold thrombosis when compared with metallic DES.

Table 1. Bioresorbable Scaffold Technologies in Clinical Practice.

Igaki-Tamai Scaffold Kyoto Medical	DREAMS I/ Biotronik	Bioresorbable Vascular Scaffold/ Abbott Vascular	DESolve scaffold/ Elixir	ReZolve scaffold/ REVA Medical	BTI scaffold/ (-)	ART 18Z scaffold/ ART
						
FIM Trial	FIM Trial	FIM Trial	FIM Trial	FIM Trial	FIM Trial	FIM Trial
Igaki-Tamai FIM	BIOSOLVE-1	Absorb Cohort B	DeSolve 1	RESTORE	Whisper	ARTDIVA
Strut Thickness	Strut Thickness	Strut Thickness	Strut Thickness	Strut Thickness	Strut Thickness	Strut Thickness
170 µm	150 µm	150 µm	150 µm	150 µm	200 µm	170 µm
Alloy	Alloy	Alloy	Alloy	Alloy	Alloy	Alloy
Poly-L-lactic acid	Magnesium	Poly-L-lactic acid	Poly-L-lactic acid	Tyrosine poly-carbonate	Poly-salicylic acid	Poly-D-L-lactic acid
Drug-elution	Drug-elution	Drug-elution	Drug-elution	Drug-elution	Drug-elution	Drug-elution
(-)	Paclitaxel	Everolimus	Myolimus	Sirolimus	Sirolimus	(-)
Radiopacity	Radiopacity	Radiopacity	Radiopacity	Radiopacity:	Radiopacity	Radiopacity
Gold markers	Platinum markers	Platinum markers	Platinum markers	Iodination of tyrosine	(-)	(-)
Loss Index	Lumen Loss (mm)	Lumen Loss	Lumen Loss	Lumen Loss	Lumen Loss	Lumen Loss
0.48 mm (6m)	0.64 mm (6m) & 0.52 (12m)	0.19 mm (6m) & 0.29 (16m)	0.19 mm (6m)	0.29 (12m)	(-)	(-)
Resorption time	Resorption time	Resorption time	Resorption time	Resorption time	Resorption time	Resorption time
Up to 2-years	Up to 2-years	Up to 3-years	Up to 1-year	Up to 1,5 year	Up to 1-year	Up to 2-years
Regulatory approval: EU CE mark / US FDA	Regulatory approval: EU CE mark / US FDA	Regulatory approval: EU CE mark / US FDA	Regulatory approval: EU CE mark / US FDA	Regulatory approval: EU CE mark / US FDA	Regulatory approval: EU CE mark / US FDA	Regulatory approval: EU CE mark / US FDA
EU CE / -	- / -	EU CE / PMA*	EU CE / -	- / -	- / -	- / -

Advantages of transient BRS vs. permanent DES can be summarized in the:

- 1. Restoration of vessel anatomy:** BRS provide a more compliant platform which diminishes the extend of disturbed flow patterns and subsequent vascular responses over the scaffolded segments and the proximal and distal edges by limiting vascular straightening. Both vessel angulation and curvature are anticipated to be restored by the time the scaffold eliminates its radial strength. Additionally any area/ diameter mismatch causing step-up (proximal edge) or step-down (distal edge) regions which generate local anatomic alterations with subsequent oscillatory wall shear stresses (WSS) are expected to subside following scaffold resorption and further integration in the vessel wall.¹⁹⁻²³
- 2. Restoration of vessel physiology/functionality:** The liberation of the treated segment from its permanent metal cage will facilitate restoration of vessel pulsatility and vasomotion through repaired cell signaling and intact mechanotransduction (translation of mechanical forces in chemical signals) as soon as the scaffold has been completely resorbed and the lumen has entirely healed. Furthermore the adaptive mechanisms of compensatory expansive remodeling and/or lumen enlargement will not be restricted.^{23,24}
- 3. Restoration of a low thrombogenic milieu:** The risk of late or very late scaffold thrombosis will be eliminated as the foreign material (platform + coating) will have been replaced by connective tissue and the previously scaffolded segment will have been healed with matured endothelium. Late or very late stent thrombosis remains a major concern even with newer generation DES; while older generation DES like sirolimus- and paclitaxel-eluting stents retain a risk of 0.4-0.6%/year.²⁵ Additionally the phenomenon of late acquired strut malapposition observed with metallic stents, increasing the risk for late or very late stent thrombosis (attributed to compensative expansive remodeling without adequate neointimal tissue proliferation) will not be an issue following complete strut resorption.
- 4. Potential elimination of the risk of in-scaffold neoatherosclerosis and its clinical implications:** In-stent neoatherosclerosis has been observed with both metallic DES and bare-metal stents. (Figure 1) Incomplete endothelial healing with sustained endothelial dysfunction are considered as the most relevant pathogenetic mechanisms, meanwhile the exact mechanism of delayed plaque growth has not been completely understood.¹² Despite the paucity of long-term imaging data following BRS implantation, the combination of complete scaffold resorption, regenerated intact endothelium with restored vasomotion and plaque passivation will potentially eliminate the risk or subsequent clinical implications following the development of in-scaffold neoatherosclerosis.²⁶

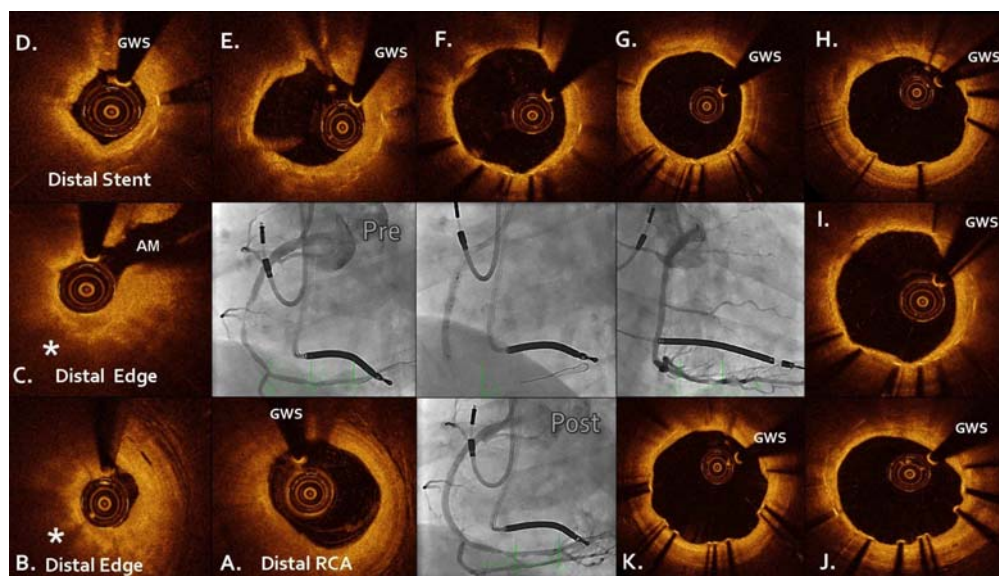


Figure 1. In-stent (distal stent edge) neoatherosclerosis 6 years after bare-metal stent implantation. Panel A: Distal right coronary artery (RCA): Pathological intimal thickening between 1-5 o'clock. Panel B: The distal edge appears to be occupied by neo-atheroma consistent with a lipid-rich plaque (white asterisk). Signs of neovascularisation are observed at 1 o'clock. Panel C: Distal edge occlusion as a consequence of plaque growth (white asterisk) at the side of the right ventricular branch take off. AM: acute marginal branch Panel D: Distal stent edge neoatherosclerosis. Panels E, F, G, H, I and K: Metallic struts at different stages of healing Panel J: Delayed strut healing.

5. Pediatric applications. Absorbable scaffolds appear as more appropriate technologies for the treatment of obstructive cardiovascular lesions in pediatric cardiology such as aortic coarctation and pulmonary artery stenosis. Permanent metallic implants limit vessel growth and require future surgical removal in contrast to bioresorbable materials which allow restoration of vessel anatomy and physiology as soon as the resorbed scaffold has been integrated in the vessel wall.

BENCHSIDE EVALUATION OF POLYMER BIORESORPTION

The term “polymer” derives from the Greek word $\text{πολύ} = \text{poly}$ (many or much) and $\text{μέρος} = \text{meros}$ (part) and refers to a molecule whose structure is composed of multiple repeating units. Polymers have specific mechanical properties defined by their tensile strength and Young's or tensile modulus of elasticity and certain phase behavior defined by their glass transition temperature (T_g) and melting point (T_m). The tensile strength quantifies the amount of stress the material will endure before suffering permanent deformation and increases by elongating and crosslinking polymer chains. The Young's modulus of elasticity quantifies the elastic properties of the polymer (measure of stiffness) and is highly dependent on temperature.

The most commonly used polymer for engineering bioresorbable scaffolds such as the Igaki-Tamai scaffold (Kyoto Medical Planning Co, Ltd. Japan), Absorb BVS (Abbott Vascular, Santa Clara, CA), DESolve scaffold (Elixir Medical Corporation, Sunnyvale, CA, US) and ART (Arterial Remodeling Technologies, Paris, France) is poly-L-lactic acid (PLLA). PLLA's tensile strength ranges between 60–70 megapascal (MPa) and the tensile modulus of elasticity between 3.1–3.7 gigapascal (GPa) while Poly-D-L-Lactic acid (PDLLA) ranges among 45–55 MPa and 3.1–3.7 GPa respectively. In terms of phase behavior PLLA T_m is 175–180°C and T_g 55–65°C. Bioresorbable metal alloys like absorbable magnesium scaffolds provide larger tensile strengths and larger tensile modulus of elasticity compared to polymer-based scaffolds in the range of 220–330 MPa and 40–45 GPa respectively. As a measure of comparison biostable metal stents either cobalt chromium or stainless steel alloys have significantly higher tensile strength and stiffness compared to bioresorbable platforms in the range of 1000 MPa and 200 GPa respectively.

PLLA is a semi crystalline polymer (maximum crystallinity = 70%) comprised of a mixture of crystalline phase and a less dense amorphous phase. The high crystallinity or linearity of the polymer defined by the degree of monomers' linear arrangement results in higher strength and slower

degradation rate compared to non linear polymer chains. Degradation occurs predominantly through hydrolysis and is bulk degradation from the inside out depending on the concentration of ester bonds, water and carboxylic acid end groups.²⁷ Hydrolytic degradation of PLLA undergoes three stages (Figure 2).^{28,29} The first stage is governed by polymer hydration. Polylactides are relatively hydrophilic thus water diffuses into the less dense amorphous regions of the implant and hydrolyses the ester bonds. Random chain scissions occur at this stage leading to a reduction of the polymer molecular weight. The second stage is characterized by continuous cleavage of the amorphous tie chains linking the crystalline regions which cause reduction in the radial strength of the scaffold causing visible structural discontinuities. During the third stage polymer chains which have been hydrolysed to short lengths diffuse out of the implant (mass loss) as they are increasingly hydrophilic and soluble in aqueous solution. Following these sequential stages oligomeric poly lactic acid molecules hydrolyze to lactic acid monomers which deprotonate (release of a proton [H⁺]) to lactate. Lactate is converted to pyruvate and enters the citric acid cycle (Krebs cycle) which is further metabolized in CO₂ and H₂O excreted through lungs and kidneys respectively.³⁰

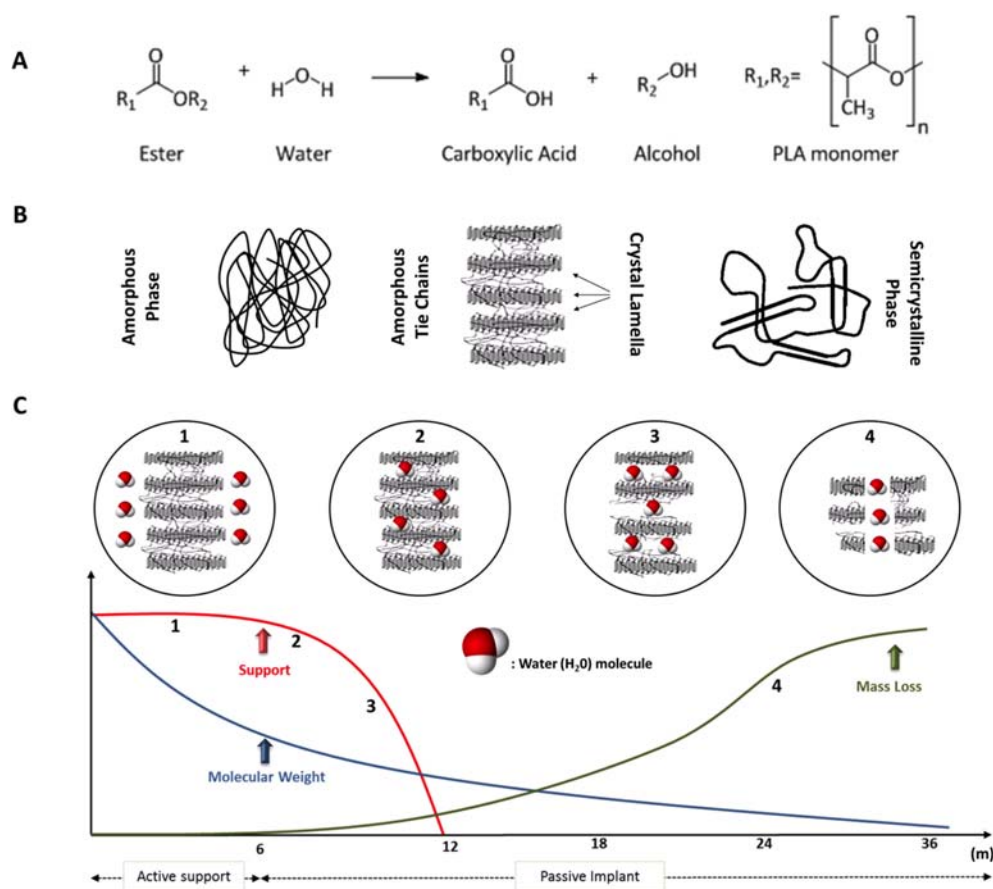


Figure 2. Bench bioresorption of poly-L-lactic acid. Panel A: The pathway of ester bond hydrolysis of poly-L-lactic acid. Panel B: Poly-L-lactic acid is semicrystalline (70% crystallinity) consisting of amorphous tie chains linking the semicrystalline phased polymer. Degradation process starts at the sites of amorphous tie chains. Panel C: Graph showing the change of radial support, molecular weight and mass loss over time following hydrolysis. The device retains its radial support until 6-months; after this time point is transformed to a passive implant with no supportive properties.

BIORESORPTION PROCESS OF POLY-L-LACTIC ACID BASED SCAFFOLDS, ASSESSED IN A PORCINE CORONARY ARTERY MODEL

The PLLA-based Absorb BVS is the only polymeric scaffold with long-term imaging evaluation using optical coherence tomography (OCT) matched with histology in a porcine coronary artery model. Thirty-five polymeric scaffolds (3.0 × 12 mm) were implanted in the main coronary arteries of 17 healthy Yucatan minipigs which underwent OCT followed by euthanasia at: post-procedure (n = 2), 28 days (n = 2), 2-year (n = 3), 3-year (n = 5) and 5-year (n = 5) follow-up.³¹ All arterial segments were

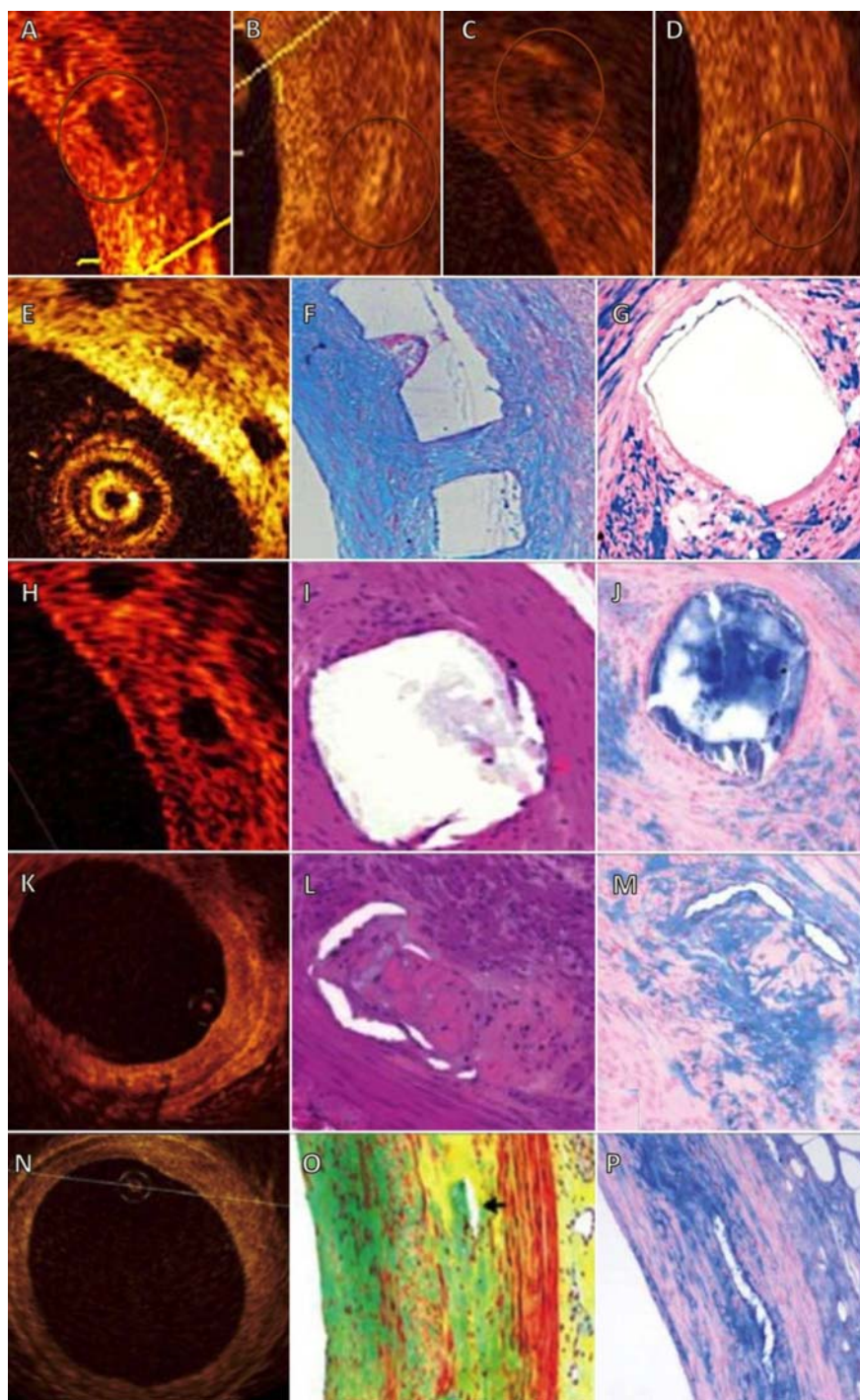


Figure 3. Optical coherence tomography (OCT) and histology at 28-days, 2-, 3- and 4-years, illustrating the bioresorption of poly lactide after Absorb BVS implantation in a porcine coronary artery model. Panels A-D: Selected cross sections demonstrating the classification of polymeric struts (Panel A) and strut voids (Panels B-D) using OCT as: black box with sharply defined borders (Panel A), open box (Panel B), dissolved black box (Panel C) and dissolved bright box (Panel D). Panels E-G: OCT cross section at 28 days shows black box appearance with sharply defined borders. Histology shows intact polymeric struts stained negative with Alcian Blue. (Panel C) Panels H-J: OCT cross section at 2-years indicates preserved box appearance; however histology at this time point shows replacement of poly lactide by proteoglycan matrix which stains positive with Alcian Blue. Panels K-M: OCT cross section at 3-years indicates the integration of strut voids within the vessel wall. Histology confirms the infiltration of connective tissue cells in the space previously occupied by strut voids which are stained positive with Hematoxylin and Eosin (Panel L) and Alcian Blue (Panel M). Panels N-P: OCT cross section at 4-years shows intact vessel wall without evidence of prior scaffolding and histology hardly detects any strut void. (Reproduced by permission: Hellenic J Cardiol 2012; 53: 301–309).

evaluated by histology except from 5 arteries assessed with gel permeation chromatography, a technique which determines the relative change of polymer's molecular weight over time. Struts imaged with OCT, had a box-shaped appearance post-implantation with sharply defined borders. At 28 days, 82% of the struts visualized with OCT remained box-shaped while by histology all struts appeared intact with no evidence of resorption. At 2-years, 80.4% still had box-shape appearance; however polylactide was not able to be detected by gel permeation chromatography. Histology illustrated that polylactide had been replaced by proteoglycan rich matrix stained positive with Alcian-Blue, an observation which introduces the term strut void or strut footprint instead of strut as the material of the scaffold is not detectable with gel permeation chromatography rather is replaced by matrix.

At 3-years, only 5.4% of strut voids were box-shaped imaged with OCT, while 43.75% showed dissolved black box, 34.8% dissolved bright box and 16.1% open box appearance. Histology at this time point showed that connective tissue within a proteoglycan rich matrix replaced the areas previously occupied by the polymeric struts. At 4-years histology revealed that strut voids are minimally discernible as foci of hypocellular connective tissue. These important observations provide evidence of complete poly-lactide resorption at 2-years, despite the visualization of sharply defined strut remnants with OCT. At 3- and 4-years both invasive OCT and histology confirmed complete integration of the strut voids into the arterial wall (Figure 3). Apart from the qualitative assessment of the bioresorption process in this porcine study, the acquired data were also used for quantitative evaluation of the vascular effects induced by the Absorb bioresorbable scaffolds utilizing OCT and histology. The main findings of this pilot substudy were: 1. histology provided systematically larger values of the quantified neointimal tissue when compared to OCT and 2. OCT and histomorphometry were both feasible and reproducible for quantitative analysis.³²

FROM BENCHSIDE TO CLINICAL APPLICATIONS: BIORESORBABLE SCAFFOLDS IN THE CLINICAL SETTING

Poly-L-Lactic Acid Igaki-Tamai Scaffold

The Igaki-Tamai (Kyoto Medical Planning Co, Ltd. Japan) scaffold was the first polymer based device which underwent first-in-man (FIM) evaluation. The scaffold material was poly-L-lactic acid, had a helical zig-zag design with sinusoidal hoops linked by 3 connectors and carried two radiopaque cylindrical gold markers at each proximal and distal ends (Figure 4A). The device was mounted over a conventional angioplasty balloon and was self-expanding following heated contrast injections (up to 70°C or 158°F) to inflate the delivery balloon. The FIM angiographic study performed in 15 patients (19 lesions, 25 scaffolds implanted) indicated absence of major adverse cardiac events (MACE) and no scaffold thrombosis at 30 days. Further evaluation at 6-months demonstrated acceptable angiographic loss index (late loss/acute gain) of 0.48 ± 0.32 which was comparable to bare metal stents and invasive imaging assessment with IVUS showed scaffold expansion from $7.42 \pm 1.51 \text{ mm}^2$ to $8.13 \pm 2.52 \text{ mm}^2$; a dynamic finding observed for the first time with coronary implantable devices.³³

TLR rates reached 6.7% (per-patient) while long-term clinical outcomes at 4-year follow-up showed MACE-free survival rates up to 82%. Very long-term follow-up (> 10 years) of an observational prospective study which evaluated 63 lesions treated with 84 Igaki-Tamai scaffolds was recently reported (Figure 4B). Ten-year MACE rate was 50% with two cases of definite scaffold thrombosis and TLR rates reached 38%.³⁴ The technology failed to further qualify for coronary revascularizations despite the Conformité Européenne (CE) mark for peripheral interventions in the European market due to the 1. use of heat to induce scaffold expansion 2. lack of drug-elution and 3. use of 8F guide catheters as the scaffold was constrained by a sheath removed only after the lesion was crossed.

Absorbable Magnesium-based scaffolds

Magnesium (Mg), the world's lightest metal is alloyed with one or more elements which include: rare earth metals, aluminum, manganese, lithium, zinc and zirconium. This class of bioresorbable devices belongs to biocorrosible metals characterized by high corrosion rates (complete biodegradation within 3 months) with end products being elemental Mg and inorganic salts (Figure 5). The earliest proof-of-mechanism which indicated the biocompatibility of such materials with vascular tissue was introduced by Heublein et al. who employed absorbable magnesium devices in porcine coronary arteries demonstrating rapid endothelialization and low inflammatory response.³⁵

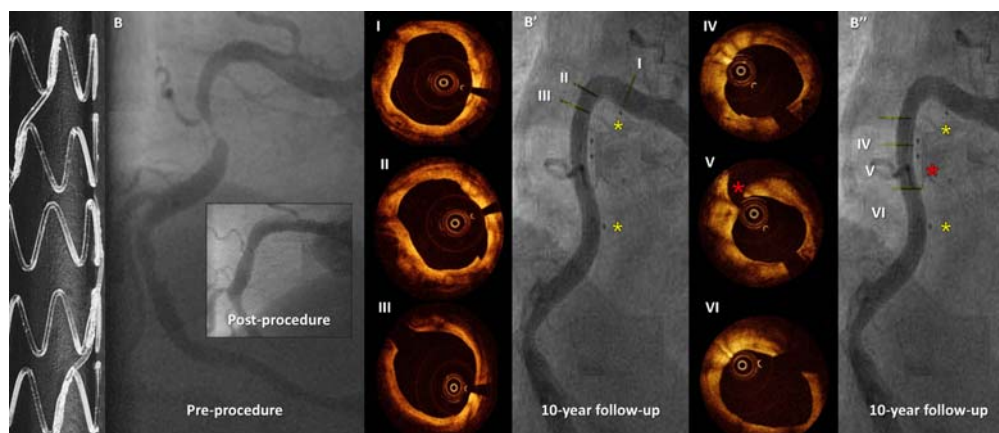


Figure 4. Ten-year follow-up of the Igaki-Tamai scaffold. Panel A. Macroscopic view of the polymeric scaffold demonstrating a helical zig-zag design interconnected with straight bridges. Panel B. Angiographic view of the right coronary artery (RCA) demonstrating a significant mid-RCA lesion pre-procedure and the excellent angiographic result post-implantation of the 2 Igaki-Tamai scaffolds. Panel B', B'': Angiographic views 10-year following implantation of the Igaki-Tamai scaffolds without evidence of in-scaffold restenosis. Yellow asterisks demonstrate the gold markers at each proximal and distal scaffold ends. Red asterisk demonstrates the outgrowth of a side branch. Panels I-VI: Optical coherence tomographic views of the RCA after 10-year of Igaki-Tamai scaffolding. A smooth lumen with no remnants of strut voids is evident. (Reproduced by permission: EuroIntervention 2009 Dec 15; 5 Suppl F: F 109-11).

The PROGRESS AMS (Clinical Performance and Angiographic Results of Coronary Stenting with Absorbable Metal Stents) was a non-randomized, multi-center, prospective FIM trial which assessed the safety, efficacy and performance of the first absorbable magnesium stent (AMS-1) (BIOTRONIK, Berlin, Germany). AMS-1 was made of 93% Mg and 7% rare earth metals, had a strut thickness of

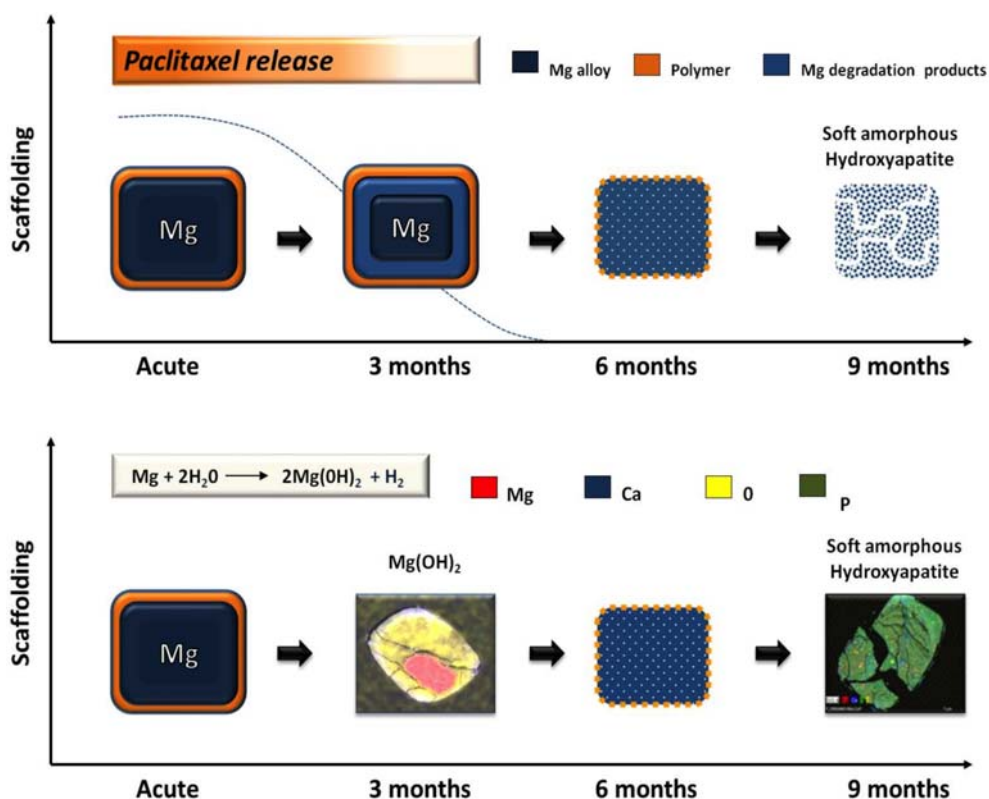


Figure 5. Schematic representation of Magnesium-based scaffold bioresorption. The end product following magnesium scaffold bioresorption facilitated by hydrolysis is amorphous hydroxyapatite. The whole process takes up to 9 months with the first generation DREAMS scaffold. Drug-elution occurs within 3 months.

165 μm and carried 2 radiopaque markers at each proximal and distal ends as the device was radiolucent. Sixty-three patients with stable coronary artery disease were treated with 71 stents. Follow-up included imaging assessment with angiography and intravascular ultrasound (IVUS) at 4-months and clinical assessment at 6- and 12-months. The angiographic in-stent lumen loss was 1.08 ± 0.49 mm at 4-months and IVUS imaging suggested that most of the struts were fully resorbed with only strut remnants being visible embedded into the intima. TLR rates were 23.8% at 4-months and reached 45% at 1-year.

Although this study demonstrated safety of AMS-1 with no reported death, myocardial infarction or stent thrombosis, imaging and clinical results raised concerns over the further use of this generation in coronary interventions as increased neointimal formation and vessel recoil became evident. Subsequently AMS-2 and AMS-3 were developed to overcome the aforementioned limitations primarily caused by the lack of drug-elution and early loss of radial strength.³⁶

AMS-2 provided an improved Mg alloy with higher collapse pressure of 1.5 bar compared to 0.8 bar of AMS-1, a slower degradation rate with expected absorption after 9-12 months and reduced strut thickness of 125 μm with rectangular shape to enhance stent integrity. The AMS-3 was designed to address the issue of previously observed intense neointimal hyperplasia, thus a bioresorbable matrix for controlled release of paclitaxel was added to the previous AMS-2. The new device was named drug-eluting AMS (DREAMS) 1.0 (BIOTRONIK, Bulach, Switzerland) and was evaluated for safety, feasibility and efficacy in the prospective, multicenter, FIM BIOSOLVE-1 trial. (Safety and Performance of the Drug-Eluting Absorbable Metal Scaffold (DREAMS) in Patients with de-novo Coronary Lesions).³⁷ Forty-six patients with stable/unstable coronary artery disease or silent ischemia were treated with 47 stents. Imaging follow-up included angiography and IVUS at 6- and 12- months and clinical assessment was scheduled at 1-, 6-, 12-, 24- and 36-months. The angiographic in-stent lumen loss was 0.64 ± 0.50 mm at 6-months and 0.52 ± 0.49 mm at 1-year which represents a 61% reduction compared to the 4-month results of AMS-1.

Serial IVUS imaging confirmed the angiographic observations showing in-scaffold area obstruction of only 6.24% ($p < 0.0001$) at 1-year attributed to neointimal formation with extra-scaffold plaque area increase. TLR rates reached 7% with no reported episodes of stent thrombosis up to 3-year follow-up. The 2nd generation DREAMS device has been recently developed which elutes sirolimus instead of paclitaxel, carries two tantalum radiopaque markers at both ends and provides higher bending flexibility and slower resorption rate compared to the previous generation. Pre-clinical data are encouraging showing increased endothelialization rates and decreased inflammatory scores and the BIOSOLVE-II study has been designed to assess the safety, efficacy and feasibility of this generation in 120 patients with follow-up investigations scheduled at 1-, 6-, 12-, 24- and 36-months. The primary endpoint of this trial is in-segment late lumen loss and following completion regulatory approval for CE mark will be requested for in coronary interventions in the European market.

Poly-L-Lactic Acid Absorb Bioresorbable Vascular Scaffold

The Absorb bioresorbable vascular scaffolds (BVS) (Abbott Vascular, Santa Clara, CA) include the 1st generation Absorb BVS 1.0 and 2nd generation Absorb BVS 1.1 devices evaluated for safety, feasibility and efficacy in the ABSORB Cohort A and B (B1 + B2) clinical trials respectively (Figure 6). Both devices have a polymer backbone made of semicrystalline PLLA and a polymer coating of lower crystallinity made of poly-D-L- lactic acid that controls the release of the antiproliferative agent everolimus. (Novartis, Basel, Switzerland). The design of the 1st generation device had circumferential out-of-phase sinusoidal hoops linked either directly or by straight polymeric bridges. The strut thickness including the polymer-drug coating was 156 μm and the crossing profile 1.4 mm (crimped stage) slightly larger compared to that of contemporary metallic stents. The device had to be kept refrigerated at -4°F to prevent early aging as room temperature was a precipitating factor for polymer cracking during scaffold deployment.³⁰

The performance of this device was evaluated in 30 patients with simple de novo native coronary artery disease. Follow-up included invasive angiography, IVUS, virtual histology – IVUS (VH-IVUS) and optical coherence tomography (OCT) at 6-months and 2-years and clinical endpoints were assessed at 6-months, 1- and 2-years. CCTA at 18-months and 5-years was also performed. The angiographic in-scaffold lumen loss was 0.44 ± 0.35 mm at 6-months more than this observed with metallic everolimus-eluting stents (0.11 mm) and far less than bare-metal stents (0.85 mm).³⁸ IVUS imaging assessment indicated significant reduction of scaffold area (scaffold shrinkage) by 11.8% with some

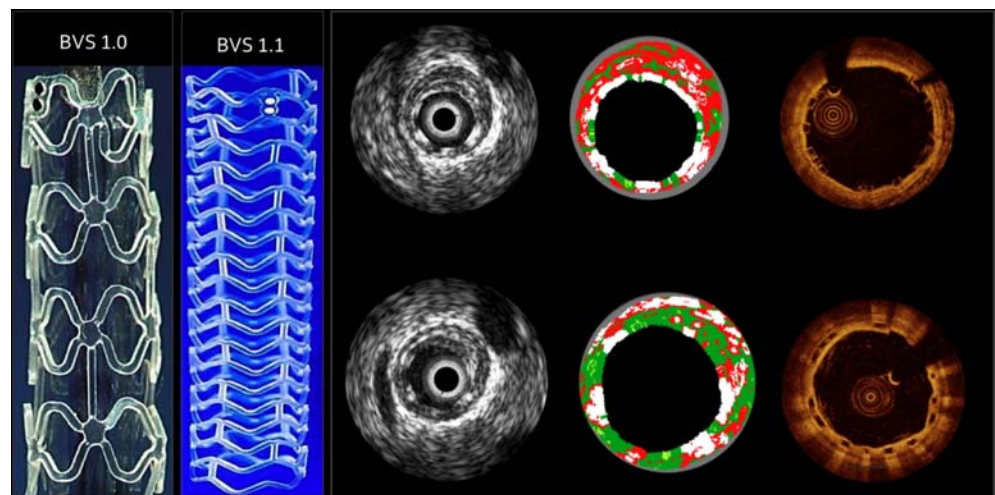


Figure 6. Multi imaging assessment of the Absorb Bioresorbable Vascular Scaffold (BVS) The Absorb BVS 1.0 was the first generation device used in the Absorb Cohort A trial. The second generation Absorb BVS 1.1 has been redesigned and is currently under clinical use. Intravascular imaging modalities like IVUS, VH-IVUS and OCT have provided important insights in the evaluation of bioresorbable scaffolds. The top panel of cross sections shows IVUS, VH-IVUS and OCT following Absorb BVS implantation while the bottom panel at 6-month follow-up. Polymeric materials compared to metal materials are not reflecting sound or light thus shadow behind the struts is not visible. Guide wires and platinum markers are the only components which create shadow over the circumference of the cross section. VH-IVUS detects polymeric struts as dense calcium tissue component similar to metal stents; meanwhile in contrast to metal stents this unique property is used as a surrogate marker of bioresorption with biodegradable scaffolds.

degree of neointimal tissue which resulted in 24.3% reduction in minimal luminal area.³⁹ At 2-years the in-scaffold angiographic LL did not change significantly compared to the short-term observations (0.48 ± 0.28 mm) while additional important findings were: 1. Restoration of vasoreactivity of the scaffolded segment in response to methergin or acetylcholine, 2. Plaque area reduction between 6-months and 2-years 3. Low MACE rate of 3.4% up to 4-years without any events of scaffold thrombosis and 4. Feasibility of non-invasive imaging with CCTA.⁴⁰ Despite low event rates the early scaffold shrinkage subsequent to premature loss of radial support raised the need for development of the 2nd generation Absorb BVS.

The Revision 1.1 device was constructed from the same polymer (PLLA) as the previous generation but with a different processing which delayed the rate of ester bond hydrolysis increasing the duration of mechanical support and scaffold resorption. Strut thickness remained the same but the whole backbone was redesigned by reducing the maximum circular unsupported surface area (area between two sequential rings) showing in-phase zig-zag hoops linked by 3 longitudinal bridges that allowed more uniform vessel support. Although the implant was radiolucent had 2 platinum markers at each end for appropriate visualization during coronary angiography.

The Absorb Cohort B trial tested this generation in 101 patients. This Cohort was split in 2 subgroups: Cohort B₁ (n = 45), which underwent imaging with angiography, IVUS, VH-IVUS and OCT at post-procedure, 6-months and 2-years and Cohort B₂ (n = 56) at post-procedure, 1-year and 3-years.

Additionally CCTA was performed in both groups at 18-months follow-up. Angiographic in-scaffold lumen loss at 6-months was 0.19 ± 0.18 mm, at 2-years 0.27 ± 0.20 mm and at 3-years remained unchanged: 0.29 ± 0.43 mm. IVUS imaging revealed increase in neointimal tissue at 3-years from 0.08 ± 0.13 mm² to 0.28 ± 0.41 mm² ($\Delta = 0.20 \pm 0.41$ mm², $p < 0.002$) which was compensated by an increase in the mean scaffold area by 0.80 ± 1.26 mm² (from 6.29 ± 0.91 to 7.08 ± 1.55 mm², $p < 0.001$) thus lumen dimensions were preserved.^{41,42} The angiographic in-segment restenosis rate in the entire Cohort B at 3-years was 6% and the 3-year MACE rate 10.0% without any events of scaffold thrombosis. The results of the ABSORB Cohort B trial proved the dynamic nature of vessel wall changes following implantation of a fully bioresorbable device showing low restenosis rates and low clinical adverse events up to 3-years.⁴² Beyond ABSORB Cohort A and B trials, BVS 1.1 undergoes further evaluation in the: **1.** ABSORB Extend study (ID: NCT01023789) a multi center registry (100 non-US sites) aiming to recruit 1000 patients and assess the safety and performance of the scaffold in long lesions

(<28 mm), **2.** ABSORB II prospective randomized clinical trial (ID: NCT01425281) which intends to recruit 501 patients randomized in a 2:1 basis to either Absorb BVS or Xience Prime stent with expected completion by 2015, and **3.** ABSORB III RCT, (NCT01751906) the first non-inferiority US trial which intends to recruit 2,350 patients in 120 North American sites and compare the fully resorbable Absorb BVS vs. Xience V or Xience Prime metallic stents and **4.** ABSORB IV (NCT02173379), a prospective, randomized (1:1, Absorb BVS to XIENCE), single-blind, multi-center study, registering approximately 3000 subjects at approximately 140 sites. Comparator data from the Absorb Cohort B and SPIRIT trials among the fully resorbable Absorb BVS and a metallic platform have shown thus far that 1. Absorb BVS is more conformable inducing changes in vessel angulation and curvature at a lesser degree attributed to better platform conformability⁴³ 2. Absorb BVS causes more accentuated proximal edge response compared to a metallic platform^{44,45}. The aforementioned observations are based on small sample sizes ($n < 100$) and non-complex lesions thus need to be considered hypothesis generating rather than conclusive. The Absorb BVS 1.1 has acquired CE mark in Europe since 2012 and pre market approval in the US. US FDA regulatory consideration for full approval will most probably be submitted following completion of ABSORB III and IV randomized clinical trials.

Poly-L-Lactic Acid DESolve Scaffold:

The DESolve bioresorbable coronary scaffolds (Elixir Medical Corporation, Sunnyvale, CA, US) include the 1st generation device made of PLLA eluting the immunosuppressive and antiproliferative agent myolimus (Novartis, Basel, Switzerland) at a 3 $\mu\text{g}/\text{mm}$ dose and the 2nd generation device which incorporates the same platform but elutes a novel macrocyclic lactone novolimus (Elixir medical Corporation, Sunnyvale, CA, US) at a dose of 5 $\mu\text{g}/\text{mm}$. The scaffold design incorporates sinusoidal in-phase hoops with straight connectors, the strut thickness is 150 μm and the expected strut resorption is 1-year as previously shown in porcine models. Despite the radiolucency of the device it has 2 radiopaque platinum markers at each proximal and distal edges for appropriate visualization. Both systems have a crossing profile of 1.47 mm and are 6-F compatible. Degradation process resembles that of Absorb BVS undergoing polymer hydrolysis, and further metabolism in the Krebs cycle to end products, carbon dioxide and water. The DESolve myolimus-eluting scaffold was tested for efficacy, feasibility and safety in the DESolve FIM trial (A Non-randomized, Consecutive Enrollment Evaluation of the DESolve Myolimus Eluting Bioresorbable Coronary Stent in the Treatment of Patients With de novo Native Coronary Artery Lesions) which enrolled 16 patients with a single de novo coronary lesion. Multi imaging assessment with IVUS, VH-IVUS and OCT was serially performed at 6-month follow-up. CCTA was performed at 12-months and will be repeated at 24-months while clinical endpoints were assessed at 30 days, 6 months, and will be assessed annually up to 5-years.⁴⁶ The angiographic late lumen loss at 6-month follow-up was 0.19 ± 0.19 mm similar to that of contemporary DES with no evidence of scaffold shrinkage as indicated with serial IVUS assessment. CCTA at 12-month demonstrated comparable in-scaffold lumen diameters with the angiographically derived 6-month results (2.40 ± 0.28 mm vs. 2.41 ± 0.28 mm respectively). In view of these encouraging results the second generation novolimus-eluting scaffold was developed which was further evaluated in the DESolve Nx study. 126 patients with single de novo coronary artery lesions were recruited. In-scaffold late lumen loss which was the primary end point was 0.21 ± 0.34 mm at 6 months and IVUS based assessment in a subset of 40 patients indicated significant increase in scaffold and lumen areas of 16% and 9% respectively. DESolve[®] scaffold has only acquired CE mark approval for coronary interventions in Europe.

Poly (anhydride-ester) Comprised of Salicylic Acid for Engineering Bioresorbable Scaffolds

Poly (anhydride-esters) are biodegradable polymeric compounds comprised of a trimer of two salicylic acid molecules joined by a linker molecule. The Bioabsorbable Therapeutic Inc. (BTI) scaffold (Bioabsorbable Therapeutic Inc. Menlo Park, CA, USA) consists of two components: 1. the core composed of salicylic acid bridged with sebacic acid and 2. the coating composed of salicylic acid linked with adipic acid and 1:1 ratio of sirolimus in a total dose density of 8.3 $\mu\text{g}/\text{mm}$ of scaffold length (Figure 7). The bioresorbable coating which is salicylate-based has been previously proved its compatibility and efficacy in bench studies showing reduced inflammatory responses compared to bare metal stents (Multi Link Vision stent) attributed to the salicylic acid compound which is an anti-inflammatory agent.⁴⁷ The scaffold has a strut thickness of 200 μm , a crossing profile of 1.83 mm (3.0-mm scaffold) and 1.98 mm (3.5-mm scaffold) being compatible with 8F guiding catheters. The

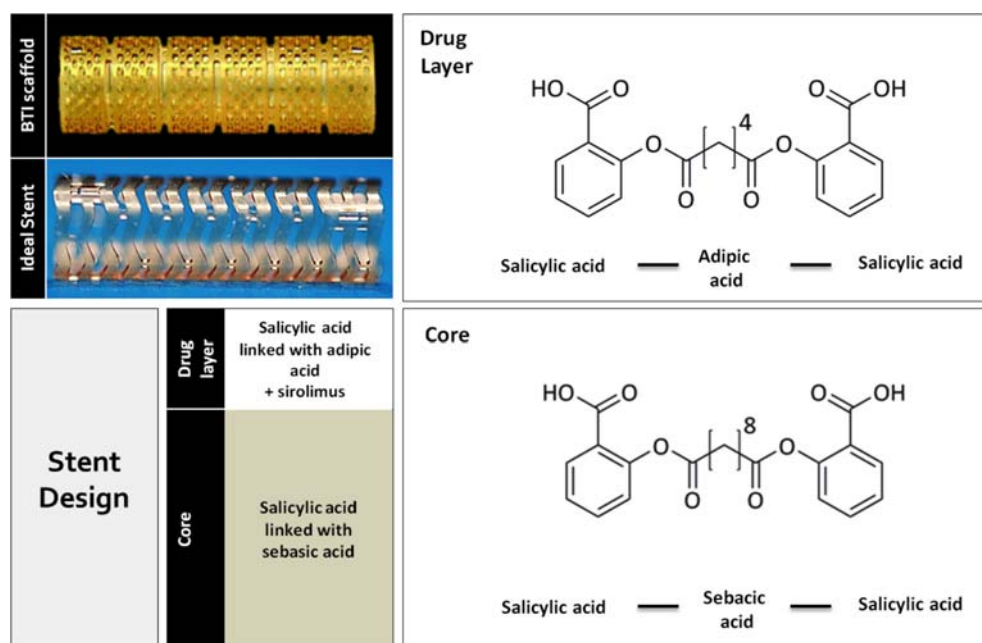


Figure 7. Poly (anhydride ester) salicylic acid for engineering bioresorbable scaffolds. The first generation BTI scaffold and the 2nd generation Ideal Biostent are shown. The scaffolds are composed of a top layer which is a blend of polymer (salicylic acid linked with adipic acid) and sirolimus and another layer which is the scaffold backbone made of salicylic acid linked with sebacic acid. The chemical structures of poly anhydride esters made of salicylic acid are illustrated.

WHISPER FIM trial conducted in 2008 included 11 patients and confirmed the safety and efficacy of the device meanwhile high restenosis rates attributed to exaggerated neointimal hyperplasia as a consequence of lower sirolimus dose (25% that of Cypher stent) drove the development of the 2nd generation scaffold.⁴⁸ The Ideal BioStent (Xenogenics Corporation, Canton, MA, US) is thinner with thickness 175 μm , smaller crossing profile (1.52 mm for 3.0 mm scaffold) which makes it compatible with 6F guiding catheters and a higher drug dose of sirolimus per scaffold length associated with slower release rates. Preclinical evaluation of the device is currently under way with plans for clinical assessment in 2015. The Poly (anhydride-ester) comprised of salicylic acid scaffold has acquired neither CE mark or US FDA regulatory approval.

Tyrosine-Derived Polymers for Engineering Polymeric Scaffolds

Tyrosine derived poly-carbonates are a group of homologous carbonate-amid copolymers differing in the length of their respective alkyl ester pendent chains. The REVA scaffold (REVA Medical, Inc, San Diego, Calif, US) is made of tyrosine derived poly-carbonate polymer having a particular design with slide-and-lock expansion technology. The polymer undergoes hydrolysis which produces iodinated desaminotyrosyl-tyrosine ethyl ester (I_2DTE) and carbon dioxide. The esters in the presence of H_2O are further hydrolyzed to iodinated desaminotyrosyl-tyrosine (I_2DT) which are gradually converted to tyrosine and iodinated desaminotyrosine (I_2DAT). I_2DAT enters the Krebs cycle with final products carbon dioxide and water (Figure 8). The resorption pathway is similar to that of poly lactic acid based scaffolds with early loss of polymer's molecular weight mediated by hydrolysis, followed by reduction of radial strength and gradual mass loss. Resorption time may take up to 18 months. Preclinical evaluation of the scaffold with scanning electron microscopy has shown low inflammatory rates and complete endothelialization at 30 days and serial IVUS imaging confirmed lumen gain from 3.65 mm^2 to 8.28 mm^2 at 12 months.

These encouraging observations drove the technology in the clinical setting with the FIM RESORB (REVA Endovascular Study of a Bioresorbable Coronary Stent) trial being performed in 30 patients with de novo coronary artery disease. Focal mechanical failure of the technology due to polymer embrittlement led to high TLR rates of 66.7% which drove the development of second generation device, ReZolve™ (REVA Medical, Inc, San Diego, Calif, US) scaffold.

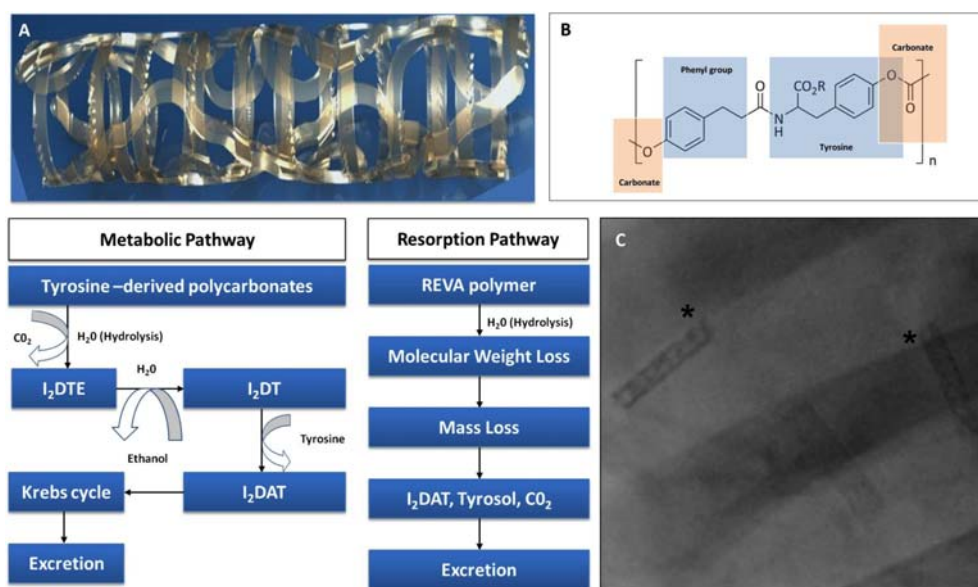


Figure 8. Tyrosine-Derived Polymers for engineering bioresorbable scaffolds. Panel A: The ReZolve (second generation) tyrosine derived polycarbonate scaffold showing the “slide and spiral lock” design. Panel B: The chemical structure of the amino acid tyrosine, carbonate and phenyl group which provide the backbone for the tyrosine derived poly-carbonate polymer. Panel C: The ReZolve scaffold is radio-opaque attributed to the iodination of tyrosine. The metabolic pathway of tyrosine derived poly-carbonates undergoes hydrolysis with end products carbon dioxide and water. The Resorption pathway is similar to PLA based scaffolds with initial loss of molecular weight followed by mass loss and excretion by the lungs and kidneys.

ReZolve provided a more robust polymer, acquired “slide and spiral lock” mechanism, eluted the antiproliferative agent sirolimus and was compatible with 6F guiding catheters. The safety of this scaffold was evaluated in the FIM RESTORE (ReZolve Sirolimus-Eluting Bioresorbable Coronary Scaffold) pilot study which included 22 patients. The primary endpoint was freedom from ischemic-driven TLR at 6-months and angiographic late lumen loss at 12-months which was 0.29 ± 0.33 mm with minimal acute recoil of 3.79%. These observations moved the technology to the ReZolve2 multicenter clinical program which has been developed to recruit 125 patients intending to assess MACE rate at 6- and 12-months and late lumen loss at 9-months. The REVA scaffold has acquired neither CE mark or US FDA regulatory approval.⁴⁹

Poly-D-L-lactic acid ART Scaffold

The ART (Arterial Remodeling Technologies, Paris, France) scaffold is a polymer based, non drug-eluting device made of amorphous PDLLA. The scaffold has a strut thickness of $170 \mu\text{m}$, consists of out of phase zig-zag hoops and is compatible with 6F guiding catheters. Preclinical assessment has shown early endothelialization, limited inflammation and complete scaffold resorption at 18 months. The 2nd generation ART18Z is currently undergoing FIM evaluation in the ARTDIVA (Arterial Remodeling Transient Dismantling Vascular Angioplasty) (ID: NCT01761578) trial intending to recruit 30 patients with de novo coronary artery disease.⁵⁰

THE ADVENT OF RESTORATION IN INTERVENTIONAL CARDIOVASCULAR MEDICINE

Restoration of vessel anatomy:

Scaffold material properties, strut thickness, length of elements and connection design are all individual variables that control flexibility and subsequently influence the extend of vascular responses at the stented/scaffolded segments and the proximal and distal edges. An important design element of conformable platforms is flexibility, which allows reasonable deliverability to distal anatomies during the acute phase inducing alterations of angulation, curvature and vessel compliance at a lesser degree by the stage where the bioresorbable scaffold loses its structural integrity.

The impact of stiff metallic materials in vessel anatomy was firstly described by Wentzel et al., showing alterations of vessel geometry following stenting with subsequent unfavorable rheologic implications. More specific Wall-stent (Boston Scientific, MA, US) changed the inflow (proximal edge)

and outflow (distal edge) three-dimensional (3D) geometry by 121% and 100% respectively inducing low WSS regions associated with development of focal neointimal hyperplasia and asymmetric patterns of in-stent restenosis.

Polymer and magnesium-based BRS are made of elastic materials providing a more conformable platform compared to metal stents. This was demonstrated within the BIOSOLVE-1 trial where DREAMS scaffold generated significant change in curvature from pre- to post-procedure by -32.1% , ($p < 0.0001$) which was restored to the pre-implantation levels at 12-month follow-up. Vessel angulation similarly changed significantly by -40.5% , ($p < 0.0001$) from pre- to post-procedure (vessel straightening) and increased by 33.1% at 12 month follow-up. In the ABSORB Cohort B trial the Absorb BVS compared to a metal alloy (Multi-link Vision or Xience V, Abbott Vascular, Santa Clara, California) showed better conformability with changes in angulation and curvature to a lesser extent.⁴³ In the same cohort the influence of enhanced conformability on the edge vascular responses was investigated by serial IVUS-based imaging showing a dynamic profile with signs of constrictive remodeling at the proximal edge at 1-year and lumen loss of 6.68% at 2-years.⁴⁵

These observations reflect the transient nature of anatomic changes and subsequent vascular responses induced by transient scaffolds which from a rheological stand point potentially restore unidirectional flow patterns over the scaffolded segments and the transition zones as the bioresorption process evolves over time. The beneficial hemodynamic implications of conformable and bioresorbable materials may minimize the flow dependent changes of wall shear stress which contribute to neointimal formation and subsequent silent or clinical restenosis⁵¹ meanwhile this hypothesis generating concept remains to be addressed within the RESTORATION trial. (Evaluation and Comparison of Three-Dimensional Wall Shear Stress Patterns and Neointimal Healing Following Percutaneous Coronary Intervention with Absorb™ Everolimus-Eluting Bioresorbable Vascular Scaffold Compared to Xience V® or Xience Prime™ Everolimus-Eluting Metallic Stent) RESTORATION is the imaging substudy of ABSORB III clinical trial which intends to address the aforementioned issues following implantation of a fully resorbable scaffold vs. a metal stent. This head to head comparison will demonstrate for the first time the association of 3-dimensional local hemodynamic conditions with subsequent vascular responses assessed with high resolution light-based imaging (Figure 9).

Restoration of vessel physiology/functionality:

Metal stent implantation has been associated with impaired vasomotion primarily observed at the distal stent edge attributed to poor endothelial coverage. In the ASORB Cohort A trial at 2-years and ABSORB Cohort B and BIOSOLVE-1 trials at 1-year follow-up, endothelial dependent vasomotion assessed with acetylcholine infusion revealed restoration of vasodilatory reactivity within the scaffolded segments.⁵² These observations provide indirect evidence of functional endothelial healing which may potentially eliminate the future risk of late or very late scaffold thrombosis attributed to delayed coverage. The latter remains to be elucidated in large scale randomized trials with strong clinical end points such as late or very late scaffold thrombosis in the setting of long-term follow-up.

Restoration of local hemodynamic milieu:

Three-dimensional design simulations of coronary implants utilizing mathematical and computational algorithms have emerged as important tools for understanding the biomechanical device properties. The hemodynamic implications following implantation of bioresorbable scaffolds using finite element methods and advanced computational fluid dynamics simulations to visualize device-flow interaction immediately after implantation and following scaffold resorption over time was recently shown. Three-dimensional simulations with time averaged wall shear stress quantifications following virtual scaffold deployment and virtual bioresorption in idealized straight and curved geometries indicated the change in local hemodynamic conditions with restoration of normalized flow patterns over the scaffolded segments and the proximal and distal edges. Such hemodynamic device modeling is expected to guide future bioresorbable scaffold design.⁵³

Allowance of non-invasive imaging:

The metal free struts of polymer-based scaffolds allow non-invasive assessment with CCTA and physiologic evaluation with fractional flow reserve based on CCTA acquisitions following scaffold implantation. In the ABSORB Cohort A trial 30 patients with a single de novo coronary lesion treated

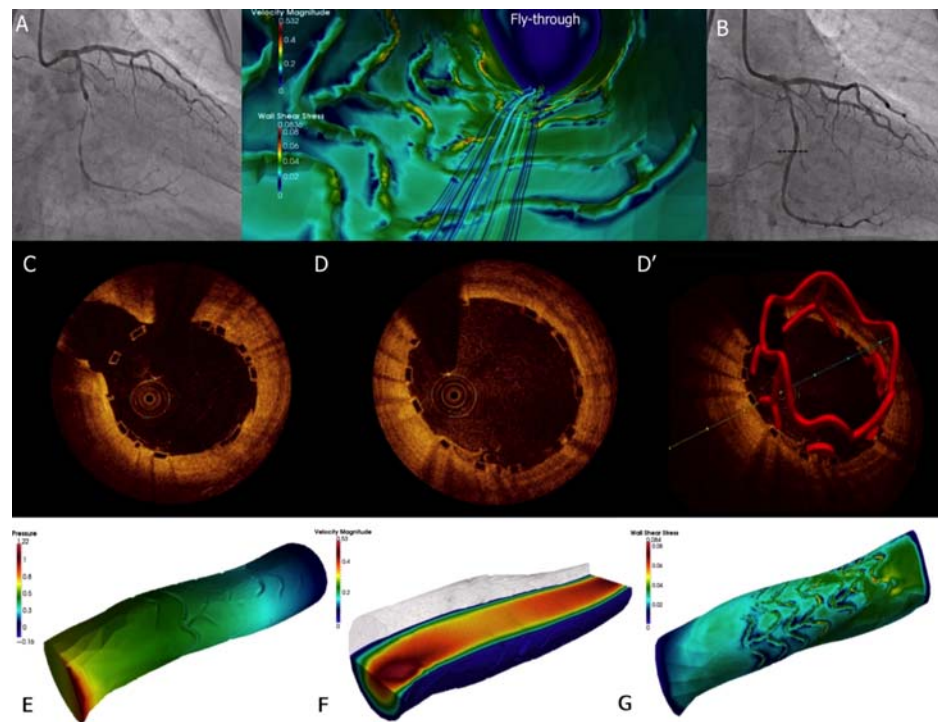


Figure 9. Three-dimensional evaluation of local hemodynamic conditions and subsequent vascular responses derived from optical coherence tomographic imaging. Panels A, B: Angiographic projections of a treated mid LCx lesion with Absorb BVS. Panel C: Selected OCT cross section at the side branch take-off (dotted line of Panel B) showing the optimally deployed scaffold. Panel D, D': Selected OCT two-dimensional cross-sections visualizing the three-dimensional appreciation of the deployed scaffold applying mathematical algorithms. Panels E, F, G: computational fluid dynamics domains following properly applied boundary conditions visualizing three-dimensional wall shear stress reconstructions.

with a fully resorbable polymeric scaffold underwent CCTA at 18-months and 5-year following scaffold deployment. Non-invasive evaluation of the overall PCI procedure with physiologic assessment proved to be feasible and comparable to invasive results. These observations indicate the alternative use of non-invasive imaging combined with physiologic assessment to identify the significance of scaffolded lesions at follow-up and highlight the importance of computational modeling and mathematical simulations in interventional cardiology practice.⁵⁴

Challenges with current generation bioresorbable scaffolds

“Undoubtedly metal stents revolutionized the practice of interventional cardiology over the last decade; meanwhile there is growing evidence of late clinical events attributed to late restenosis, late or very late stent thrombosis and in-stent neoatherosclerosis which potentially affect their long-term safety and overall performance. Although BRS appear appealing alternatives to metal stents in specific lesion and population subsets with potential long-term benefits attributed to full resorption and subsequent long-term restoration of vascular functionality further improvements are anticipated to optimize their overall performance.

Strut thickness and strut integrity:

Strut thickness and shape (rectangular, circular, elliptical or tear-drop) is an important determinant of TLR and clinical restenosis,^{55,56} thus current generation DES approved by the US FDA are manufactured with thinner struts in the range of $\sim 90\mu\text{m}$. (Xience V[®] everolimus-eluting stent, Abbott Vascular, SC, Calif.). Bulky struts may cause side-branch jailing or occlusion,⁵⁷ delayed endothelialization in particular with overlapping scaffolds and stacked struts,⁵⁸ and increased mechanical stresses over the vessel wall.⁵⁵ BRS were firstly introduced in the European interventional market with strut thickness similar to that of Cypher metallic stents ($\sim 150\mu\text{m}$) to maintain their mechanical properties, as these materials have inferior tensile strength compared to cobalt-chromium, platinum chromium or stainless steel alloys. However the latter increases their overall crossing profile at the crimped stage, induces

more intense vascular responses when deployed and restricts deliverability in tortuous anatomies, calcified lesions and small vessels (< 2.5 mm).

Polymer-based scaffolds have limited expansion properties and over dilation entails the risk of strut fracture or discontinuity⁵⁹. It is imperative for operators who implant BRS to perform aggressive lesion preparation, size correctly the vessel by using quantitative coronary angiography and select the most appropriate scaffold size as post-dilation with high inflation pressures is restricted.⁶⁰ This is particularly important with the wider utilization of BRS in more complex lesions like bifurcations or left main disease and ST segment elevation acute coronary syndromes.

Cost-effectiveness of a novel technology in the setting of US healthcare reform

More than 1 million PCI procedures were performed in the US healthcare system in 2004 following FDA approval of 1st generation DES by April 2003 with costs generally 3 to 4 times more compared to PCIs with bare-metal stents. Meanwhile the overall projected cost with DES was compensated by reducing the economic burden of restenosis which by BMS implantation was 16.9% in the first year.⁶¹ Increased competition among large medical device companies reduced further the costs of newer generation DES and it was recently shown that higher index expenditures of DES versus BMS were completely offset by lower TLR related costs.⁶² BRS in Europe, Asia-Pacific and South-America are priced generally 2 to 3 times more compared to newer generation DES; however the broad clinical application of these technologies in the US market will only be achieved by showing comparable cost-effectiveness and quality-adjusted life years with current generation DES.

CONCLUSION

BRS have been heralded as the forth revolution in interventional cardiovascular medicine following drug-eluting stents, bare-metal stents and balloon angioplasty. Although these technologies are still in the development stage further innovations in scaffold design and material properties will mature this novel field of vascular restoration therapy with more efficacious scaffolds which “do their job and disappear”.

Acknowledgements

The author would like to acknowledge and express sincere appreciation to Dr. Evelyn Regar, Dr. Boris Warnack, Mr. Michael Zapien, Mr. Richard Klein, Dr. Joan Zeltinger.

REFERENCES

- [1] Gruntzig A. Transluminal dilatation of coronary-artery stenosis. *Lancet* Feb 4 1978;1(8058):263.
- [2] Serruys PW, de Jaegere P, Kiemeneij F, Macaya C, Rutsch W, Heyndrickx G, Emanuelsson H, Marco J, Legrand V, Materne P, Belardi J, Sigwart U, Colombo A, Jacques Goy J, van den Heuvel P, Delcan J, Morel M-A. A comparison of balloon-expandable-stent implantation with balloon angioplasty in patients with coronary artery disease. Benestent Study Group. *The New England Journal of Medicine*. Aug 25 1994;331(8):489–495.
- [3] Farooq V, Gogas BD, Serruys PW. Restenosis: delineating the numerous causes of drug-eluting stent restenosis. *Circ Cardiovasc Interv*. Apr 1 2011;4(2):195–205.
- [4] Joner M, Finn AV, Farb A, Mont EK, Kolodgie FD, Ladich E, Kutys R, Skoriya K, Gold HK, Virmani R. Pathology of drug-eluting stents in humans: delayed healing and late thrombotic risk. *J Am Coll Cardiol*. Jul 4 2006;48(1):193–202.
- [5] Camenzind E, Steg PG, Wijns W. Stent thrombosis late after implantation of first-generation drug-eluting stents: a cause for concern. *Circulation* Mar 20 2007;115(11):1440–1445; discussion 1455.
- [6] Palmerini T, Biondi-Zoccai G, Della Riva D, Stettler C, Sangiorgi D, D’Ascenzo F, Kimura T, Briguor C, Sabatè M, Kim HS, De Waha A, Kedhi E, Smits PC, Kaiser C, Sardella G, Marullo A, Kirtane AJ, Leon MB, Stone GW. Stent thrombosis with drug-eluting and bare-metal stents: evidence from a comprehensive network meta-analysis. *Lancet* Apr 14 2012;379(9824):1393–1402.
- [7] Finn AV, Nakazawa G, Joner M, Kolodgie FD, Mont EK, Gold HK, Virmani R. Vascular responses to drug eluting stents: importance of delayed healing. *Arteriosclerosis, Thrombosis, and Vascular Biology*. Jul 2007;27(7):1500–1510.
- [8] Raber L, Magro M, Stefanini GG, Kalesan B, van Domburg RT, Onuma Y, Wenaweser P, Daemen J, Meier B, Jüni P, Serruys PW, Windecker S. Very late coronary stent thrombosis of a newer-generation everolimus-eluting stent compared with early-generation drug-eluting stents: a prospective cohort study. *Circulation* Mar 6 2012;125(9):1110–1121.
- [9] Garg S, Serruys PW. Coronary stents: looking forward. *Journal of the American College of Cardiology*. Aug 31 2010;56(10 Suppl):S43–78.
- [10] Pendyala LK, Yin X, Li J, Chen JP, Chronos N, Hou D. The first-generation drug-eluting stents and coronary endothelial dysfunction. *JACC. Cardiovascular Interventions*. Dec 2009;2(12):1169–1177.
- [11] Obata JE, Kitta Y, Takano H, Kodama Y, Nakamura T, Mende A, Kawabata K, Saitoh Y, Fujioka D, Kobayashi T, Yano T, Kugiyama K. Sirolimus-eluting stent implantation aggravates endothelial vasomotor dysfunction in the infarct-related

- coronary artery in patients with acute myocardial infarction. *Journal of the American College of Cardiology*. Oct 2 2007;50(14):1305–1309.
- [12] Park SJ, Kang SJ, Virmani R, Nakano M, Ueda Y. In-stent neoatherosclerosis: a final common pathway of late stent failure. *Journal of the American College of Cardiology*. Jun 5 2012;59(23):2051–2057.
- [13] Serruys PW, Garg S, Abizaid A, Ormiston J, Windecker S, Verhey S, Dubois C, Stewart J, Hauptmann KE, Schofer J, Stangl K, Witzendichler B, Wiemer M, Barbato E, de Vries T, den Drijver AM, Otake H, Meredith L, Toyloy S, Fitzgerald P. A randomised comparison of novolimus-eluting and zotarolimus-eluting coronary stents: 9-month follow-up results of the EXCELLA II study. *EuroIntervention: Journal of EuroPCR in Collaboration with the Working Group on Interventional Cardiology of the European Society of Cardiology*. Jun 2010;6(2):195–205.
- [14] Windecker S, Serruys PW, Wandel S, Buszman P, Trznadel S, Linke A, Lenk K, Ischinger T, Klauss V, Eberli F, Corti R, Wijns W, Morice MC, di Mario C, Davies S, van Geuns RJ, Eerdman P, van Es GA, Meier B, Jüni P. Biolimus-eluting stent with biodegradable polymer versus sirolimus-eluting stent with durable polymer for coronary revascularisation (LEADERS): a randomised non-inferiority trial. *Lancet* Sep 27 2008;372(9644):1163–1173.
- [15] Serruys PW, Farooq V, Kalesan B, de Vries T, Buszman P, Linke A, Ischinger T, Klauss V, Eberli F, Wijns W, Morice MC, Di Mario C, Corti R, Antoni D, Sohn HY, Eerdman P, Rademaker-Havinga T, van Es GA, Meier B, Jüni P, Windecker S. Improved safety and reduction in stent thrombosis associated with biodegradable polymer-based biolimus-eluting stents versus durable polymer-based sirolimus-eluting stents in patients with coronary artery disease: final 5-year report of the LEADERS (Limus Eluted From A Durable Versus ERodable Stent Coating) randomized, noninferiority trial. *JACC. Cardiovascular Interventions*. Aug 2013;6(8):777–789.
- [16] Gogas BD, McDaniel M, Samady H, King SB 3rd. Novel drug-eluting stents for coronary revascularization. *Trends in Cardiovascular Medicine*. Oct 2014;24(7):305–313.
- [17] Wykrzykowska JJ, Onuma Y, Serruys PW. Vascular restoration therapy: the fourth revolution in interventional cardiology and the ultimate “rosy” prophecy. *EuroIntervention: Journal of EuroPCR in Collaboration with the Working Group on Interventional Cardiology of the European Society of Cardiology*. Dec 15 2009;5(Suppl F):F7–8.
- [18] van der Giessen WJ, Lincoff AM, Schwartz RS, van Beusekom HM, Serruys PW, Holmes DR Jr, Ellis SG, Topol EJ. Marked inflammatory sequelae to implantation of biodegradable and nonbiodegradable polymers in porcine coronary arteries. *Circulation* Oct 1 1996;94(7):1690–1697.
- [19] Koskinas KC, Chatzizisis YS, Antoniadis AP, Giannoglou GD. Role of endothelial shear stress in stent restenosis and thrombosis: pathophysiologic mechanisms and implications for clinical translation. *Journal of the American College of Cardiology*. Apr 10 2012;59(15):1337–1349.
- [20] Thury A, Wentzel JJ, Vinke RV, Gijssen FJ, Schuurbiens JC, Krams R, de Feyter PJ, Serruys PW, Slager CJ. Images in cardiovascular medicine. Focal in-stent restenosis near step-up: roles of low and oscillating shear stress? *Circulation* Jun 11 2002;105(23):e185–187.
- [21] Coronary artery surgery study (CASS): a randomized trial of coronary artery bypass surgery. Quality of life in patients randomly assigned to treatment groups. *Circulation* Nov 1983;68(5):951–960.
- [22] Van der Heiden K, Gijssen FJ, Narracott A, Hsiao S, Halliday I, Gunn J, Wentzel JJ, Evans PC. The effects of stenting on shear stress: relevance to endothelial injury and repair. *Cardiovascular Research*. Jul 15 2013;99(2):269–275.
- [23] Brugaletta S, Heo JH, Garcia-Garcia HM, Farooq V, van Geuns RJ, de Bruyne B, Dudek D, Smits PC, Koolen J, McClean D, Dorange C, Veldhof S, Rapoza R, Onuma Y, Bruining N, Ormiston JA, Serruys PW. Endothelial-dependent vasomotion in a coronary segment treated by ABSORB everolimus-eluting bioresorbable vascular scaffold system is related to plaque composition at the time of bioresorption of the polymer: indirect finding of vascular reparative therapy? *European Heart Journal*. Jun 2012;33(11):1325–1333.
- [24] Hahn C, Schwartz MA. Mechanotransduction in vascular physiology and atherogenesis. *Nature Reviews. Molecular Cell Biology*. Jan 2009;10(1):53–62.
- [25] Sarno G, Lagerqvist B, Frobert O, Nilsson J, Olivecrona G, Omerovic E, Saleh N, Venetznos D, James S. Lower risk of stent thrombosis and restenosis with unrestricted use of ‘new-generation’ drug-eluting stents: a report from the nationwide Swedish Coronary Angiography and Angioplasty Registry (SCAAR). *Eur Heart J*. Mar 2012;33(5):606–613.
- [26] Brugaletta S, Radu MD, Garcia-Garcia HM, Heo JH, Farooq V, Girasis C, van Geuns RJ, Thuesen L, McClean D, Chevalier B, Windecker S, Koolen J, Rapoza R, Miquel-Hebert K, Ormiston J, Serruys PW. Circumferential evaluation of the neointima by optical coherence tomography after ABSORB bioresorbable vascular scaffold implantation: can the scaffold cap the plaque? *Atherosclerosis* Mar 2012;221(1):106–112.
- [27] Oberhauser JP, Hossainy S, Rapoza RJ. Design principles and performance of bioresorbable polymeric vascular scaffolds. *EuroIntervention* Dec 15 2009;5(Suppl F):F15–22.
- [28] Gopferich A. Mechanisms of polymer degradation and erosion. *Biomaterials* Jan 1996;17(2):103–114.
- [29] Vorpahl M, Finn AV, Nakano M, Virmani R. The bioabsorption process: tissue and cellular mechanisms and outcomes. *EuroIntervention: Journal of EuroPCR in Collaboration with the Working Group on Interventional Cardiology of the European Society of Cardiology*. Dec 15 2009;5(Suppl F):F28–35.
- [30] Gogas BD, Farooq V, Onuma Y, Serruys PW. The ABSORB bioresorbable vascular scaffold: an evolution or revolution in interventional cardiology? *Hellenic J Cardiol*. Jul-Aug 2012;53(4):301–309.
- [31] Onuma Y, Serruys PW, Perkins LE, Okamura T, Gonzalo N, Garcia-Garcia HM, Regar E, Kamberi M, Powers JC, Rapoza R, van Beusekom H, van der Giessen W, Virmani R. Intracoronary optical coherence tomography and histology at 1 month and 2, 3, and 4 years after implantation of everolimus-eluting bioresorbable vascular scaffolds in a porcine coronary artery model: an attempt to decipher the human optical coherence tomography images in the ABSORB trial. *Circulation* Nov 30 2010;122(22):2288–2300.
- [32] Gogas BD, Radu M, Onuma Y, Perkins L, Powers JC, Gomez-Lara J, Farooq V, Garcia-Garcia HM, Diletti R, Rapoza R, Virmani R, Serruys PW. Evaluation with in vivo optical coherence tomography and histology of the vascular effects of the everolimus-eluting bioresorbable vascular scaffold at two years following implantation in a healthy porcine coronary artery model: implications of pilot results for future pre-clinical studies. *Int J Cardiovasc Imaging*. Mar 2012;28(3):499–511.

- [33] Tamai H, Igaki K, Kyo E, Kosuga K, Kawashima A, Matsui S, Komori H, Tsuji T, Motohara S, Uehata H. Initial and 6-month results of biodegradable poly-L-lactic acid coronary stents in humans. *Circulation* Jul 25 2000;102(4):399–404.
- [34] Nishio S, Kosuga K, Igaki K, Okada M, Kyo E, Tsuji T, Takeuchi E, Inuzuka Y, Takeda S, Hata T, Takeuchi Y, Kawada Y, Harita T, Seki J, Akamatsu S, Hasegawa S, Bruining N, Brugaletta S, de Winter S, Muramatsu T, Onuma Y, Serruys PW, Ikeguchi S. Long-Term (>10 Years) clinical outcomes of first-in-human biodegradable poly-L-lactic acid coronary stents: Igaki-Tamai stents. *Circulation* May 15 2012;125(19):2343–2353.
- [35] Heublein B, Rohde R, Kaese V, Niemeyer M, Hartung W, Haverich A. Biocorrosion of magnesium alloys: a new principle in cardiovascular implant technology? *Heart* Jun 2003;89(6):651–656.
- [36] Erbel R, Di Mario C, Bartunek J, Bonnier J, de Bruyne B, Eberli FR, Erne P, Haude M, Heublein B, Horrigan M, Ilesley C, Böse D, Koolen J, Lüscher TF, Weissman N, Waksman R. Temporary scaffolding of coronary arteries with bioabsorbable magnesium stents: a prospective, non-randomised multicentre trial. *Lancet* Jun 2 2007;369(9576):1869–1875.
- [37] Haude M, Erbel R, Erne P, Verheye S, Degen H, Böse D, Vermeersch P, Wijnbergen I, Weissman N, Prati F, Waksman R, Koolen J. Safety and performance of the drug-eluting absorbable metal scaffold (DREAMS) in patients with de-novo coronary lesions: 12 month results of the prospective, multicentre, first-in-man BIOSOLVE-I trial. *Lancet* Mar 9 2013;381(9869):836–844.
- [38] Grube E, Sonoda S, Ikeno F, Honda Y, Kar S, Chan C, Gerckens U, Lansky AJ, Fitzgerald PJ. Six- and twelve-month results from first human experience using everolimus-eluting stents with bioabsorbable polymer. *Circulation* May 11 2004;109(18):2168–2171.
- [39] Ormiston JA, Serruys PW, Regar E, Dudek D, Thuesen L, Webster MW, Onuma Y, Garcia-Garcia HM, McGreevy R, Veldhof S. A bioabsorbable everolimus-eluting coronary stent system for patients with single de-novo coronary artery lesions (ABSORB): a prospective open-label trial. *Lancet* Mar 15 2008;371(9616):899–907.
- [40] Serruys PW, Ormiston JA, Onuma Y, Regar E, Gonzalo N, Garcia-Garcia HM, Nieman K, Bruining N, Dorange C, Miquel-Hébert K, Veldhof S, Webster M, Thuesen L, Dudek D. A bioabsorbable everolimus-eluting coronary stent system (ABSORB): 2-year outcomes and results from multiple imaging methods. *Lancet*. Mar 14 2009;373(9667):897–910.
- [41] Ormiston JA, Serruys PW, Onuma Y, van Geuns RJ, de Bruyne B, Dudek D, Thuesen L, Smits PC, Chevalier B, McClean D, Koolen J, Windecker S, Whitbourn R, Meredith I, Dorange C, Veldhof S, Hebert KM, Rapoza R, Garcia-Garcia HM. First serial assessment at 6 months and 2 years of the second generation of absorb everolimus-eluting bioresorbable vascular scaffold: a multi-imaging modality study. *Circ Cardiovasc Interv*. Oct 2012;5(5):620–632.
- [42] Serruys PW, Onuma Y, Garcia-Garcia HM, Muramatsu T, van Geuns RJ, de Bruyne B, Dudek D, Thuesen L, Smits PC, Chevalier B, McClean D, Koolen J, Windecker S, Whitbourn R, Meredith I, Dorange C, Veldhof S, Hebert KM, Rapoza R, Ormiston JA. Dynamics of vessel wall changes following the implantation of the Absorb everolimus-eluting bioresorbable vascular scaffold: a multi-imaging modality study at 6, 12, 24 and 36 months. *EuroIntervention* Dec 3 2013;.
- [43] Gomez-Lara J, Garcia-Garcia HM, Onuma Y, Garg S, Regar E, De Bruyne B, Windecker S, McClean D, Thuesen L, Dudek D, Koolen J, Whitbourn R, Smits PC, Chevalier B, Dorange C, Veldhof S, Morel MA, de Vries T, Ormiston JA, Serruys PW. A comparison of the conformability of everolimus-eluting bioresorbable vascular scaffolds to metal platform coronary stents. *JACC Cardiovascular Interventions*. Nov 2010;3(11):1190–1198.
- [44] Gogas BD, Bourantas CV, Garcia-Garcia HM, Onuma Y, Muramatsu T, Farooq V, Diletti R, van Geuns RJ, De Bruyne B, Chevalier B, Thuesen L, Smits PC, Dudek D, Koolen J, Windecker S, Whitbourn R, McClean D, Dorange C, Miquel-Hébert K, Veldhof S, Rapoza R, Ormiston JA, Serruys PW. The edge vascular response following implantation of the Absorb everolimus-eluting bioresorbable vascular scaffold and the XIENCE V metallic everolimus-eluting stent. First serial follow-up assessment at six months and two years: insights from the first-in-man ABSORB Cohort B and SPIRIT II trials. *EuroIntervention: Journal of EuroPCR in Collaboration with the Working Group on Interventional Cardiology of the European Society of Cardiology*. Oct 22 2013;9(6):709–720.
- [45] Gogas BD, Garcia-Garcia HM, Onuma Y, Muramatsu T, Farooq V, Bourantas CV, Serruys PW. Edge vascular response after percutaneous coronary intervention: an intracoronary ultrasound and optical coherence tomography appraisal: from radioactive platforms to first- and second-generation drug-eluting stents and bioresorbable scaffolds. *JACC Cardiovascular Interventions*. Mar 2013;6(3):211–221.
- [46] Verheye S, Ormiston JA, Stewart J, Webster M, Sanidas E, Costa R, Costa JR Jr, Chamie D, Abizaid AS, Pinto I, Morrison L, Toyloy S, Bhat V, Yan J, Abizaid A. A Next-Generation Bioresorbable Coronary Scaffold System-From Bench to First Clinical Evaluation: Six- and 12-Month Clinical and Multimodality Imaging Results. *JACC Cardiovasc Interv*. 2014 Jan;7(1):89–99.
- [47] Jabara R, Chronos N, Robinson K. Novel bioabsorbable salicylate-based polymer as a drug-eluting stent coating. *Catheter Cardiovasc Interv*. Aug 1 2008;72(2):186–194.
- [48] Jabara R, Pendyala L, Geva S, Chen J, Chronos N, Robinson K. Novel fully bioabsorbable salicylate-based sirolimus-eluting stent. *EuroIntervention* Dec 15 2009;5(Suppl F):F58–64.
- [49] Zeltinger J. Bio-Mechanical properties & ABC of Tyrosine polycarbonate. PCR FOCUS GROUP 2012. Oral presentation.
- [50] Lafont A, Durand E. A.R.T.: concept of a bioresorbable stent without drug elution. *EuroIntervention* Dec 15 2009;5(Suppl F):F83–87.
- [51] Waksman R, Prati F, Bruining N, Haude M, Böse D, Kitabata H, Erne P, Verheye S, Degen H, Vermeersch P, Di Vito L, Koolen J, Erbel R. Serial observation of drug-eluting absorbable metal scaffold: multi-imaging modality assessment. *Circ Cardiovasc Interv*. Dec 1 2013;6(6):644–653.
- [52] Serruys PW, Onuma Y, Dudek D, Smits PC, Koolen J, Chevalier B, de Bruyne B, Thuesen L, McClean D, van Geuns RJ, Windecker S, Whitbourn R, Meredith I, Dorange C, Veldhof S, Hebert KM, Sudhir K, Garcia-Garcia HM, Ormiston JA. Evaluation of the second generation of a bioresorbable everolimus-eluting vascular scaffold for the treatment of de novo coronary artery stenosis: 12-month clinical and imaging outcomes. *Journal of the American College of Cardiology*. Oct 4 2011;58(15):1578–1588.
- [53] Gogas BD, Yang B, Passerini T, Veneziani A, Piccinelli M, Espirito G, Rasoul-Arzrumly E, Awad M, Mekonnen G, Hung OY, Holloway B, McDaniel M, Giddens DP, King SB III, Samady H. Computational Fluid Dynamics Applied to Virtually

- Deployed Drug-Eluting Coronary Bioresorbable Scaffolds. Clinical Translations Derived from a Proof-of-Concept. *GCSP* Dec 31 2014;2014(4):56.
- [54] Nieman K, Serruys PW, Onuma Y, van Geuns R-J, Garcia-Garcia HM, de Bruyne B, Thuesen L, Smits PC, Koolen JJ, McClean D, Chevalier B, Meredith I, Ormiston J. Multislice computed tomography angiography for noninvasive assessment of the 18-month performance of a novel radiolucent bioresorbable vascular scaffolding device: the ABSORB trial (a clinical evaluation of the bioabsorbable everolimus eluting coronary stent system in the treatment of patients with de novo native coronary artery lesions). *J Am Coll Cardiol*. Nov 5 2013;62(19):1813–1814.
- [55] Kastrati A, Mehilli J, Dirschinger J, Dotzer F, Schühlen H, Neumann FJ, Fleckenstein M, Pfafferott C, Seyfarth M, Schömig A. Intracoronary stenting and angiographic results: strut thickness effect on restenosis outcome (ISAR-STEREO) trial. *Circulation* Jun 12 2001;103(23):2816–2821.
- [56] Pache J, Kastrati A, Mehilli J, Schühlen H, Dotzer F, Hausleiter J, Fleckenstein M, Neumann FJ, Sattelberger U, Schmitt C, Müller M, Dirschinger J, Schömig A. Intracoronary stenting and angiographic results: strut thickness effect on restenosis outcome (ISAR-STEREO-2) trial. *J Am Coll Cardiol*. Apr 16 2003;41(8):1283–1288.
- [57] Muramatsu T, Onuma Y, Garcia-Garcia HM, Farooq V, Bourantas CV, Morel MA, Li X, Veldhof S, Bartorelli A, Whitbourn R, Abizaid A, Serruys PW. Incidence and short-term clinical outcomes of small side branch occlusion after implantation of an everolimus-eluting bioresorbable vascular scaffold: an interim report of 435 patients in the ABSORB-EXTEND single-arm trial in comparison with an everolimus-eluting metallic stent in the SPIRIT first and II trials. *JACC Cardiovasc Interv*. Mar 2013;6(3):247–257.
- [58] Farooq V, Serruys PW, Heo JH, Gogas BD, Onuma Y, Perkins LE, Diletti R, Radu MD, Räber L, Bourantas CV, Zhang Y, van Remortel E, Pawar R, Rapoza RJ, Powers JC, van Beusekom HM, Garcia-Garcia HM, Virmani R. Intracoronary optical coherence tomography and histology of overlapping everolimus-eluting bioresorbable vascular scaffolds in a porcine coronary artery model: the potential implications for clinical practice. *JACC. Cardiovascular Interventions*. May 2013;6(5):523–532.
- [59] Ormiston JA, De Vroey F, Serruys PW, Webster MW. Bioresorbable polymeric vascular scaffolds: a cautionary tale. *Circ Cardiovasc Interv*. Oct 1 2011;4(5):535–538.
- [60] Farooq V, Gomez-Lara J, Brugaletta S, Gogas BD, Garcia-Garcia HM, Onuma Y, van Geuns RJ, Bartorelli A, Whitbourn R, Abizaid A, Serruys PW. Proximal and distal maximal luminal diameters as a guide to appropriate deployment of the ABSORB everolimus-eluting bioresorbable vascular scaffold: a sub-study of the ABSORB Cohort B and the on-going ABSORB EXTEND Single Arm Study. *Catheter Cardiovasc Interv*. May 1 2012;79(6):880–888.
- [61] Ryan J, Cohen DJ. Are drug-eluting stents cost-effective? It depends on whom you ask. *Circulation* Oct 17 2006;114(16):1736–1743, discussion 1744.
- [62] Schafer PE, Sacrinty MT, Cohen DJ, Kutcher MA, Gandhi SK, Santos RM, Little WC, Applegate RJ. Cost-effectiveness of drug-eluting stents versus bare metal stents in clinical practice. *Circ Cardiovasc Qual Outcomes*. Jul 2011;4(4):408–415.