



OPEN ACCESS

Images in cardiology

# Antegrade flow in Anomalous Left Coronary Artery from Pulmonary Artery: Clinical implications

Yasser Sedky<sup>1</sup>, Hatem Hosny<sup>2</sup>, Mohamed Donya<sup>3</sup>, Sherin AbdElsalam<sup>1</sup>, Magdi Yacoub<sup>4,\*</sup>

## ABSTRACT

Anomalous origin of the left main coronary artery from the pulmonary artery (ALCAPA) is a rare congenital anomaly that usually presents in childhood. It results in left ventricular (LV) ischemia with resulting LV dysfunction. This ischemia results from retrograde flow into the pulmonary artery which can act as a coronary steal. We here report antegrade flow detected in ALCAPA caused by severe pulmonary hypertension. Anatomic correction of ALCAPA is the preferred surgical option and should be performed as early as possible.

<sup>1</sup>Division of Pediatric Cardiology, Aswan Heart Center, Aswan, Egypt

<sup>2</sup>Division of Cardiac Surgery, Aswan Heart Center, Aswan, Egypt

<sup>3</sup>Division of Radiology, Aswan Heart Center, Aswan, Egypt

<sup>4</sup>Imperial College, London, UK

\*Email: m.yacoub@imperial.ac.uk

<http://dx.doi.org/10.5339/gcsp.2014.45>

Submitted: 19 July 2014

Accepted: 11 September 2014

© 2014 Sedky, Hosny, Donya, AbdElsalam, Yacoub, licensee Bloomsbury Qatar Foundation Journals. This is an open access article distributed under the terms of the Creative Commons Attribution license CC BY 4.0, which permits unrestricted use, distribution and reproduction in any medium, provided the original work is properly cited.

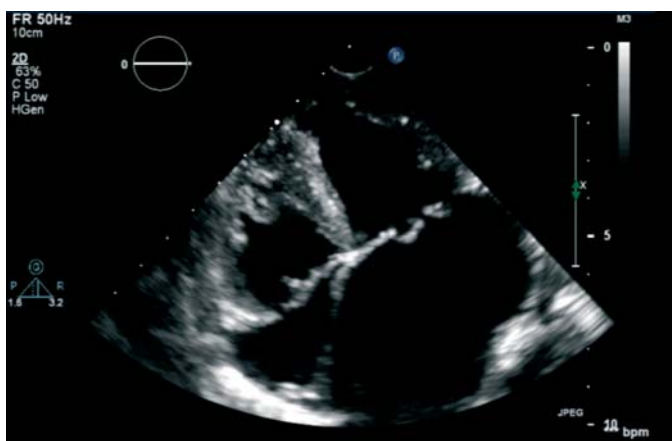
## BACKGROUND

Anomalous origin of the left main coronary artery from the pulmonary artery (ALCAPA) is a rare congenital anomaly that usually presents in childhood, also known as Bland-White-Garland syndrome, occurring in approximately 1 in 300,000 children or 0.5% of children with congenital heart disease. Ninety percent of the patients with ALCAPA die within the first year of life without surgical intervention.<sup>1</sup> The condition causes varying degrees of left ventricular (LV) ischemia with resulting LV dysfunction. The ischemia results from several factors including the retrograde flow in the anomalous vessel into the pulmonary artery (PA) which can act as a coronary steal. We here report a patient with ALCAPA in whom forward flow was observed preoperatively due to pulmonary hypertension (PHTN), secondary to severe mitral regurgitation, and discuss the implication and management plan.

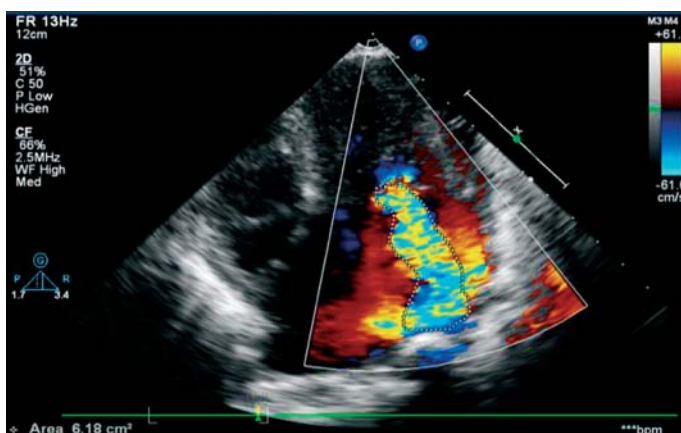
## CLINICAL REPORT

A 1.5-year-old male child presented with four months history of shortness of breath and dyspnea on exertion.

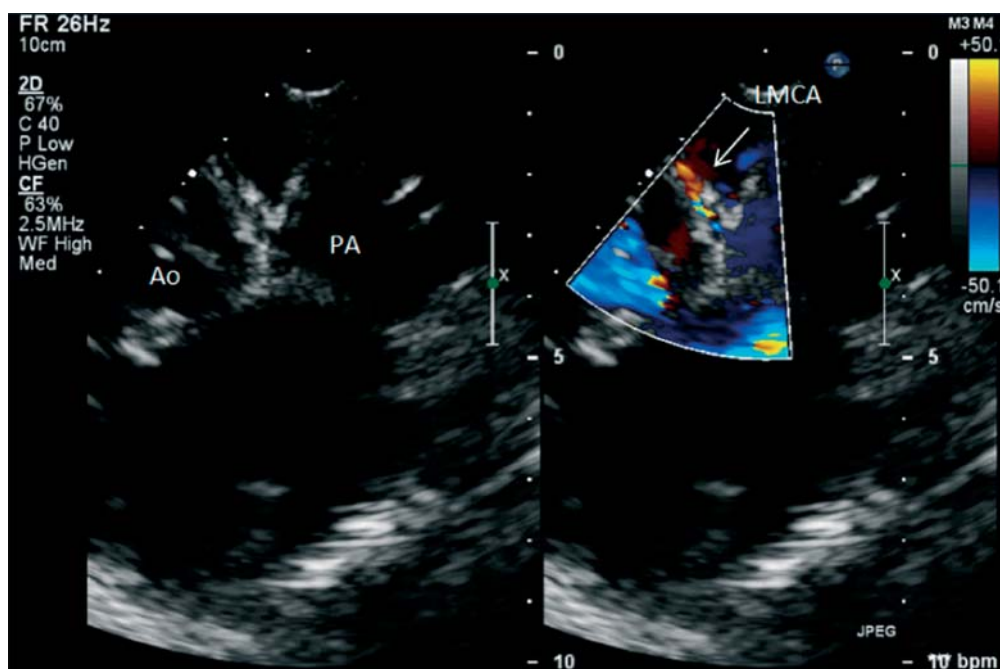
Two-dimensional color flow Doppler echocardiography revealed the presence of an abnormal mitral valve (Figure 1). The leaflets were thickened and dysplastic. The mitral annulus was significantly dilated. There was a central coaptation gap and severe MR (Figure 2). The LV was dilated with an ejection fraction of 56% and left atrial (LA) enlargement. The systolic pulmonary artery pressure was estimated to be 65 mmHg. The origin of the left main coronary artery (LMCA) seemed to arise from the pulmonary artery (PA), however there was antegrade flow in the coronaries (Figure 3).



**Figure 1.** Two-dimensional echocardiography shows the presence of an abnormal mitral valve.



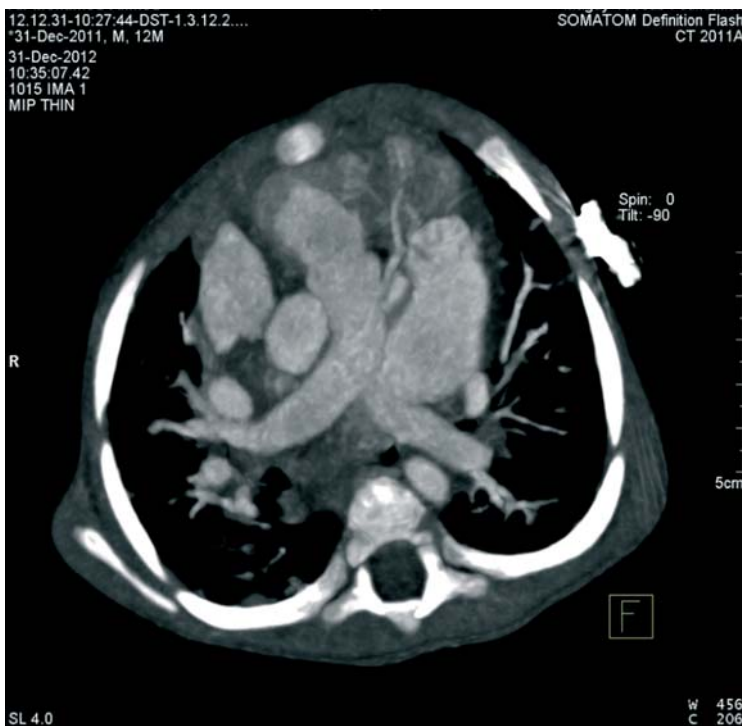
**Figure 2.** Two-dimensional color flow Doppler echocardiography shows the presence of an abnormal mitral valve with severe MR.



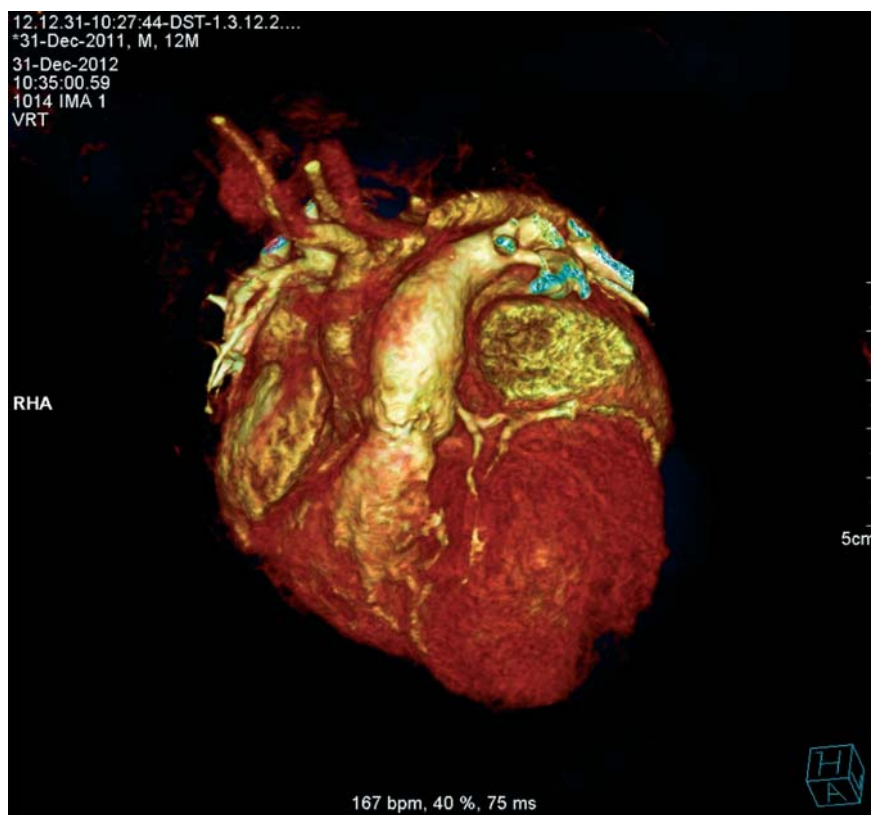
**Figure 3.** Two-dimensional color flow Doppler echocardiography shows the origin of LMCA seemed to arise from the pulmonary artery (PA) with ante grade flow.

Multi-slice computed tomography (MSCT) angiography and selective coronary angiography confirmed the origin of LMCA from pulmonary artery (Figures 4–6).

Anatomic correction of ALCAPA was performed by coronary transfer to the aorta<sup>2</sup> and mitral valve repair. The postoperative course was uneventful. Repeat MSCT showed LMCA arising from the aorta (Figure 7).



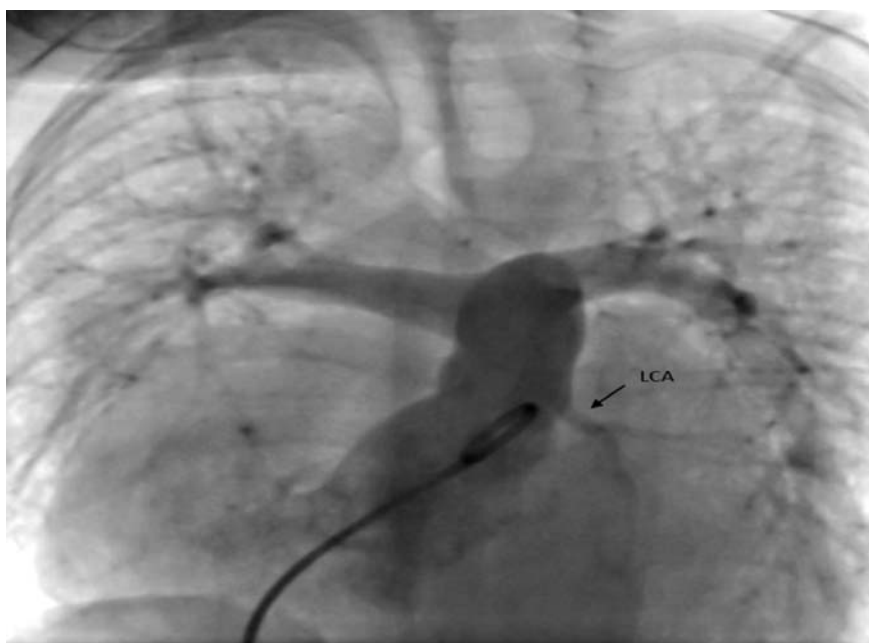**Figure 4.** MSCT angiography shows the origin of LMCA from pulmonary artery.



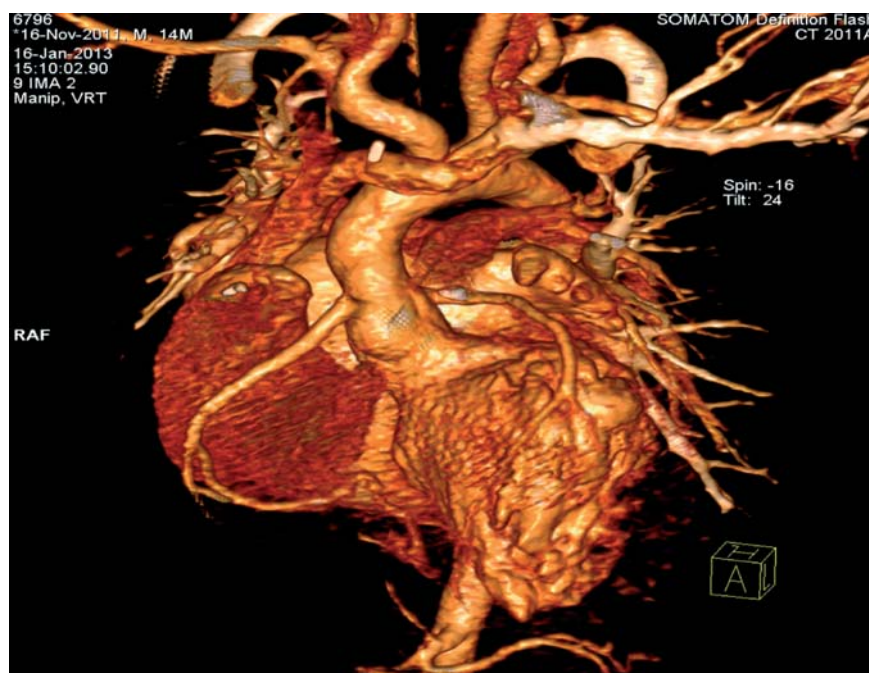
**Figure 5.** Reconstructive 3D MSCT angiography showing the origin of LMCA from pulmonary artery.

## DISCUSSION

The case presented here illustrates several important features regarding the diagnosis, pathophysiology and management of ALCAPA.



**Figure 6.** Angiography of the pulmonary artery in the antero posterior (AP) projection shows the origin of the LMCA from the pulmonary artery.



**Figure 7.** Postoperative reconstructive 3D MSCT angiography shows the origin of LMCA from the aorta.

Clinical manifestations of ALCAPA are due to myocardial ischemia, secondary to low-pressure coronary perfusion and insufficient collateral flow from the right coronary artery and reversed flow in the left coronary vessels to the pulmonary artery, which can cause coronary steal.<sup>3</sup> In the patient presented here the presence of ALCAPA with primary mitral valve abnormality resulted in several unusual features. Severe MR with the pulmonary hypertension, caused the flow in the LMCA to be antegrade. This prevented severe deterioration of LV function, in spite of the fact that part of the myocardium was perfused by deoxygenated blood.

The diagnosis is usually made by the coexistence of LV dysfunction in early life with signs of ischemia and mitral regurgitation. Echocardiographic findings include a dilated right coronary artery (RCA), detection of the coronary artery to pulmonary artery shunt by careful interrogation of the pulmonary trunk using color flow Doppler imaging, and retrograde filling of the anomalous coronary artery by both pulsed wave and color flow Doppler imaging.<sup>4</sup> In our patient, the diagnosis was made preoperatively in spite of the absence of retrograde flow by multi modality imaging.

Similar cases were reported describing antegrade flow in LMCA due to PHTN in patients with PDA, VSD or severe MR who also had ALCAPA. Treatment of the cause of PHTN in such cases, with failure to identify the diagnosis of ALCAPA, will unmask the ALCAPA and can lead to catastrophic consequences.<sup>3,5</sup>

The optimal management of ALCAPA repair aims at direct anatomic implantation of the left coronary ostium in the left sinus of Valsalva at infancy. This technique avoids using foreign material and, importantly, restores normal coronary artery – sinus of Valsalva anatomical relationship.<sup>2</sup> The correction should be done as early as possible to take advantage of fact that cardiomyocytes continue to self-proliferate for a short period after birth, as stated by Hesham Sadek and his group.<sup>6</sup>

It is hoped that the unusual features of ALCAPA presented here will help in the management of similar patients in the future.

#### REFERENCES

- [1] Keith JD. The anomalous origin of the left coronary artery from the pulmonary artery. *Br Heart J.* 1959;21(2):149–161.
- [2] El-Hamamsy I, Ibrahim M, Yacoub MH. 30-year outcome of anatomic correction of anomalous origin of the left coronary artery from the pulmonary artery. *J Am Coll Cardiol.* 2011;57(13):1493. doi:10.1016/j.jacc.2010.06.064
- [3] Awasthy N, Marwah A, Sharma R, Dalvi B. Anomalous origin of the left coronary artery from the pulmonary artery with patent ductus arteriosus: A must to recognize entity. *Eur J Echocardiogr.* 2010;11(8):E31. doi:10.1093/ejehocard/jeq039

- [4] Holley DG, Sell JE, Hougen TJ, Martin GR. Pulsed Doppler echocardiographic and color flow imaging detection of retrograde filling of anomalous left coronary artery from the pulmonary artery. *J Am Soc Echocardiogr.* 1992;5(1):85–88.
- [5] Suzuki T, Littleman FP, Gogo PB. Atypical presentation of anomalous origin of the left main coronary artery from the pulmonary artery. *Ann Thorac Surg.* 2009;88(4):1339–1341. doi:10.1016/j.athoracsur.2009.02.089
- [6] Muralidhar SA, Mahmoud AI, Canseco D, Xiao F, Sadek HA. Harnessing the power of dividing cardiomyocytes. *Glob Cardiol Sci Pract.* 2013;2013(3):212–221. doi:10.5339/gcsp.2013.29