



OPEN ACCESS

Images in cardiology

Near-fatal cardiac arrest due to cardiac tamponade during percutaneous mitral valvuloplasty

Osama Rifaie, Wail Nammas*

ABSTRACT

The incidence of hemopericardium following percutaneous mitral valvuloplasty is reported at 1–3%, being related to either trans-septal puncture, or left ventricular perforation with guide wires or balloons. We report a case of percutaneous mitral valvuloplasty for a middle-aged man with moderately severe rheumatic mitral stenosis. The procedure was performed through a right femoral vein approach, employing the multitrack technique, utilizing 2 balloons (20 and 18 mm). Inadvertently, the procedure was complicated by cardiac tamponade. Despite immediate diagnosis and prompt pericardiocentesis, hemodynamic stability was not maintained. Echocardiography revealed a mass in the posterior pericardial sac. The patient was arrested in asystole, and rigorously resuscitated during transfer to the operating room. Exploration revealed a tear in the left ventricular apex that was adequately sutured. In a few days, the patient gradually regained adequate consciousness, and was ultimately discharged. Post-procedural echocardiography revealed a mitral valve area of 1.9 cm², with no mitral regurgitation.

Keywords: percutaneous mitral valvuloplasty, cardiac tamponade, left ventricular perforation

Cardiology Department, Faculty of
Medicine, Ain Shams University,
Cairo, Egypt

*Email: wnammas@hotmail.com

[http://dx.doi.org/
10.5339/gcsp.2013.23](http://dx.doi.org/10.5339/gcsp.2013.23)

Submitted: 22 September 2012

Accepted: 14 March 2013

© 2013 Rifaie, Nammas, licensee
Bloomsbury Qatar Foundation

Journals. This is an open access
article distributed under the terms
of the Creative Commons

Attribution license CC BY 3.0, which
permits unrestricted use,
distribution and reproduction in any
medium, provided the original work
is properly cited.

CASE DESCRIPTION

A 56-year-old gentleman previously known to have rheumatic mitral stenosis, presented with a recent increase of dyspnea (New York Heart Association class III), now associated with orthopnea and paroxysmal nocturnal dyspnea. On examination, he had rapid atrial fibrillation with a pulse rate of 130/min. After control of the pulse rate with digoxin and beta blockers, echocardiography revealed a mitral valve area of 1.1 cm² by pressure half-time method, a mean diastolic pressure gradient of 18 mm Hg across the mitral valve, a total mitral valve score of 9/16, and no mitral regurgitation. Moderate calcification of the mitral valve was noted; however, since no commissural calcium was found, percutaneous mitral valvuloplasty was planned. Trans-esophageal echocardiography showed no thrombi in the left atrial appendage, a mitral valve annulus diameter of 38 mm, and a thin inter-atrial septum (2 mm).

The procedure was performed through a right femoral vein puncture, employing the multi-track technique, using 2 balloons (20 and 18 mm in diameter). Following a smooth trans-septal puncture, the mitral valve was crossed with a Judkins right catheter, and 2 wires were secured in the left ventricular apex with a double coil clearly seen in both. The 2 balloons were advanced along the wires and inflated; yet, surprisingly, no clear waist was seen (Figure 1). Skeptic about the balloon position, the operator decided to redo the inflation more proximally, wherein a clear waist was seen that ultimately yielded to balloon inflation. Suddenly, blood pressure collapsed to 80/60 mm Hg, with a slow – though still irregular – pulse rate of around 60 bpm. The patient began to feel dyspnea and became profusely sweaty. Bedside echocardiography confirmed the presence of moderate pericardial effusion so that pericardiocentesis was immediately performed (Figure 2). Roughly, 250 ml of frank red oxygenated blood were drained out of the pericardial sac. In the mean time, heparin was counteracted by protamine sulphate administration, and dopamine infusion started at a rate of 10 µg/kg/min. Blood pressure returned back to 100/60 mm Hg, and the pulse rate rose to 100 bpm. The pigtail catheter in the pericardial sac stopped to drain any more blood; however, once again, blood pressure started to drop progressively down to 60/40 mm Hg, and the pulse rate surged – now to 110 bpm. Amazingly, bedside echocardiography unveiled an echo-dense mass posterior to the left ventricle. Emergency

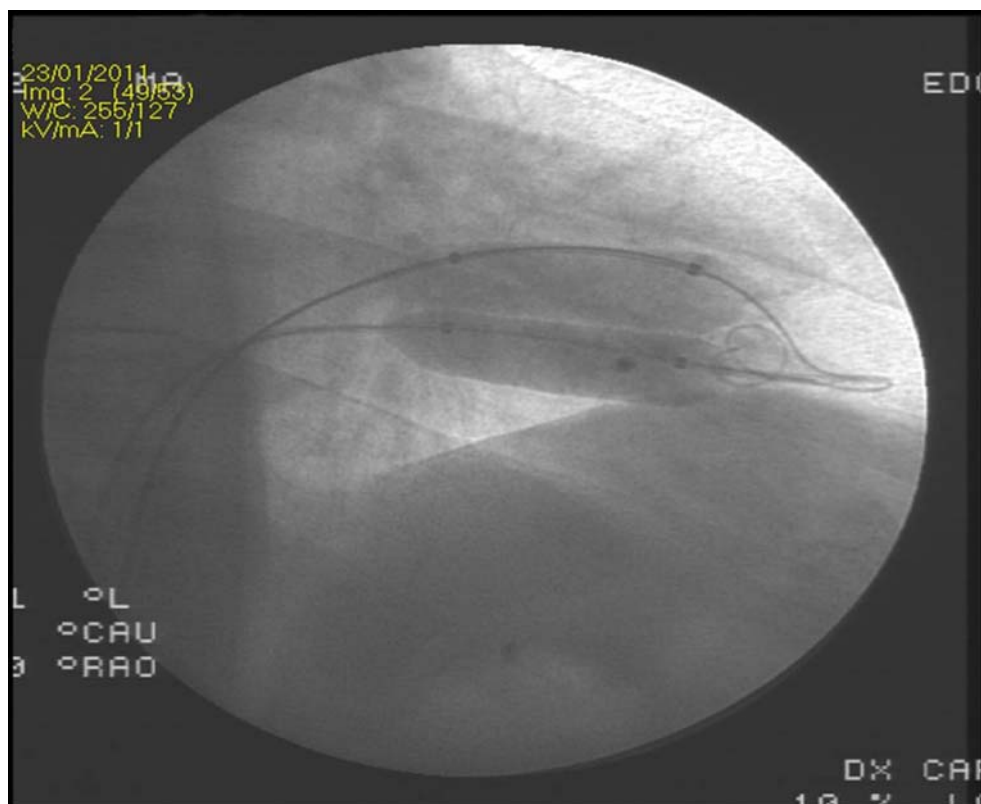


Figure 1. Fluoroscopy in right anterior oblique view showing the two balloons fully inflated with no evidence of waist. The loop of one wire is seen pointed through the left ventricular apex.

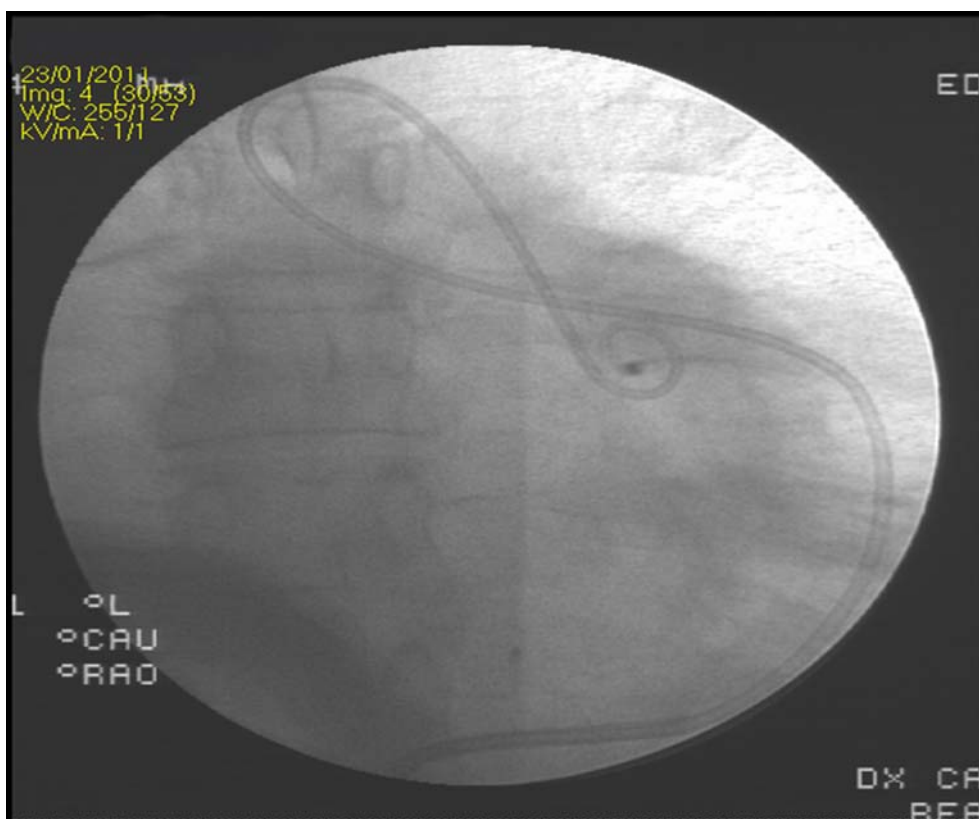


Figure 2. Fluoroscopy in right anterior oblique view showing the pigtail catheter well-positioned in the pericardial sac.

surgical intervention was promptly decided. Unfortunately, however, during transfer to the operating room, the patient was arrested in asystole. Resuscitation started straight away and continued for 15 min, well inside the operating room.

Following median thoracotomy, the surgeon was confronted with a large blood clot filling the posterior pericardial sac. The clot was removed at once; the heart restarted to beat at 70 bpm and blood pressure was restored to 100/70 mm Hg. A 1.5 cm tear was discovered in the left ventricular apex, which was sutured with Teflon sutures. Eventually, the patient was hemodynamically stable but was discharged to the intensive care unit in deep coma, wherein he was supported with mechanical ventilation. His consciousness level improved the next day, so that his Glasgow Coma Score was 6; the day after, it reached 9. Thereafter, he became fully conscious, and was disconnected off mechanical ventilation; however, he suffered some memory deficit, and mild motor dysphasia. Three days later, he regained an almost normal neurological state and was discharged from the intensive care unit. Post-procedural echocardiography revealed a mitral valve area of 1.9 cm², with no mitral regurgitation, and confirmed the absence of further accumulation in the pericardium.

DISCUSSION

Over the past two decades, percutaneous mitral valvuloplasty has emerged as the procedure of choice in 'well-selected' patients with symptomatic moderate or severe mitral stenosis.¹ The procedure is associated with mortality rates that range from 0 to 3%, chiefly due to cardiac tamponade, severe mitral regurgitation, or deterioration of the patient's general condition.² The incidence of hemopericardium following percutaneous mitral valvuloplasty is reported at 1-3%, being related to either trans-septal puncture or left ventricular perforation with guide wires or balloons.³ The site of perforation is crucial for both the immediate and long-term outcome. Frequently self-limited perforation of the right atrial appendage often responds well to pericardiocentesis, and spontaneous closure is the rule. On the other hand, left ventricular apical perforations can be swiftly fatal due to the high left ventricular pressure, especially if induced by the rigid balloon catheters rather than the guide wires,

and therefore frequently need emergency surgical repair.⁴ Careful hemodynamic monitoring is of paramount importance to early 'pick up' cases which need life-saving immediate pericardiocentesis, aided by reversal of anticoagulation by protamine sulphate, even before hemodynamic deterioration. Bedside echocardiography is the standard of care for prompt diagnosis, and should be an indispensable 'workhorse' in any cath lab that performs percutaneous mitral valvuloplasty procedures. During pericardiocentesis, one should always ensure a proper position of the pigtail catheter inside the pericardial sac, guided by fluoroscopy and bedside echocardiography. However, if the clinical condition deteriorates despite the absence of effluent from the pericardium, emergency surgical exploration would be mandatory. Moreover, it is widely acknowledged that blood in the pericardial sac does not clot due to the defibrination effect by cardiac motion. In the current case, however, rapid accumulation of a large amount of blood over a brief period of time might have been the cause of blood clotting in the posterior pericardial sac, further augmented by protamine sulphate injection.

CONCLUSION

It would be wise to inflate the balloons extremely cautiously, so that if no waist is seen, inflation should be immediately halted and the balloon catheters pulled back to a more proximal position, in order to avoid injury of the left ventricular apex.

Competing interests

None declared.

Funding sources

No funding from external sources.

REFERENCES

- [1] Prendergast BD, Shaw TRD, lung B, Vahanian A, Northridge DB. Contemporary criteria for the selection of patients for percutaneous balloon mitral valvuloplasty. *Heart*. 2002;87:401–404.
- [2] Harrison JK, Wilson JS, Hearne SE, Bashore TM. Complications related to percutaneous transvenous mitral commissurotomy. *Cathet Cardiovasc Diagn*. 1994;Suppl. 2:52–60.
- [3] Berland J, Gerber L, Gamra H, Bousadia H, Cribier A, Letac B. Percutaneous balloon valvuloplasty for mitral stenosis complicated by fatal pericardial tamponade in a patient with extreme pulmonary hypertension. *Cathet Cardiovasc Diagn*. 1989;17:109–111.
- [4] Pan M, Medina A, Suárez de Lezo J, Hernández E, Romero M, Pavlovic D, Melián F, Segura J, Román M, Montero A, Morales J, Franco M, Montijano A, Vallés F. Cardiac tamponade complicating mitral balloon valvuloplasty. *Am J Cardiol*. 1991;68:802–805.